Transbronchial Biopsy Interpretation in the Patient With Diffuse Parenchymal Lung Disease

Kevin O. Leslie, MD; James F. Gruden, MD; James M. Parish, MD; Mary Beth Scholand, MD

• ***Context.*—The most common lung tissue samples seen by pathologists worldwide are obtained with the flexible bronchoscope. Specimens taken for examination of diffuse or multifocal parenchymal lung abnormalities pose special challenges for the general surgical pathologist, and these challenges are often compounded by high clinical expectations for accurate and specific diagnosis.**

***Objective.*—To present and discuss the most common histopathologic patterns and diagnostic entities seen in transbronchial biopsy specimens in the setting of diffuse or multifocal lung disease. Specifically, acute lung injury, eosinophilic pneumonia, diffuse alveolar hemorrhage, chronic cellular infiltrates, organizing pneumonia, alveolar proteinosis, sarcoidosis, Wegener granulomatosis, intravenous drug abuse-related microangiopathy, Langerhans cell histiocytosis, and lymphangioleiomyomatosis are presented. Clinical and radiologic context is provided for the more specific diagnostic entities.**

***Data Sources.*—The published literature and experience from a consultation practice.**

***Conclusions.*—The transbronchial biopsy specimen can provide valuable information for clinical management in the setting of diffuse or multifocal lung disease. Computed tomographic scans are useful for selecting appropriate patients to undergo biopsy and in limiting the differential diagnosis. Knowledge of the clinical context, radiologic distribution of abnormalities, and histopathologic patterns is essential. With this information, the surgical pathologist can substantially influence the diagnostic workup and help guide the clinician to an accurate clinical/radiologic/pathologic diagnosis.**

(*Arch Pathol Lab Med.* 2007;131:407–423)

The flexible bronchoscope was introduced in the United States in the late 1960s and allowed pulmonologists and surgeons access to the lung as never before.[1,2] The small biopsy samples obtained with this instrument present special challenges to the general surgical pathologist, not the least of which is knowledge of the clinical and radiologic context that prompted the biopsy. In the case of diffuse or multifocal parenchymal disease, the transbronchial biopsy (TBB) approach is used, often with fluoroscopic guidance. The technique is not perfect, as the efficacy of any biopsy depends highly on the question being asked and the circumstances of the patient. For example, knowledge that the patient is immunocompromised raises the possibility of infection above all others, and requires both the use of special stains to exclude infection and a careful review of every section on the slide(s). In the normal host, knowing whether a radiologic abnormality is localized or diffuse is essential. Mild chronic inflammatory changes in a biopsy specimen taken in the setting of a spiculated mass lesion suspicious for carcinoma may be entirely incidental, whereas those same changes in a patient with diffuse parenchymal abnormalities could be a harbinger of a chronic inflammatory lung disease, or even cellular rejection in the biopsy specimen from a lung transplant recipient. Several excellent reviews of the challenges, strengths, and limitations of the TBB are available for the interested reader[3–19] and a recent overview is concisely presented by Churg.[20]

COMPUTED TOMOGRAPHY AND THE TBB

Computed tomography (CT), with scans often performed at high resolution, is very useful in predicting the yield of TBB based on the anatomic distribution and appearance of any abnormalities. In select instances, CT enables a specific diagnosis in the appropriate clinical context, particularly in patients with sarcoidosis, usual interstitial pneumonia, subacute hypersensitivity pneumonitis, acute eosinophilic pneumonia, Langerhans cell histiocytosis (LCH), and lymphangioleiomyomatosis (LAM).[21] Even when CT is nonspecific, peribronchovascular and central abnormalities are much more amenable to specific TBB diagnosis than is peripheral or nonsegmental disease. Transbronchial biopsy is also often diagnostic in patients in whom the CT findings are those of centrilobular nodules of ground-glass attenuation.[22] Unfortunately, there is still considerable variability in the performance and interpretation of thoracic CT, and the pathologist may receive tissue from a TBB in the absence of CT images or informative reports.

CLINICAL AND PROCEDURAL CONSIDERATIONS

The main utility of the TBB rests on the possibility of making a specific diagnosis in a patient with diffuse lung

Accepted for publication October 23, 2006.

From the Departments of Laboratory Medicine and Pathology (Dr Leslie), Radiology (Dr Gruden), and Medicine (Dr Parish), Division of Pulmonary Medicine, Mayo Clinic Arizona, Scottsdale; and the Department of Pulmonary and Critical Care Medicine, University of Utah School of Medicine, Salt Lake City (Dr Scholand).

The authors have no relevant financial interest in the products or companies described in this article.

Reprints: Kevin O. Leslie, MD, Department of Laboratory Medicine and Pathology, Mayo Clinic Arizona, 13400 E Shea Blvd, Scottsdale, AZ 85259 (e-mail: leslie.kevin@mayo.edu).

Downloaded from https://aplm.kglmeridian.com at 2026-03-06 via free access

disease and avoiding a surgical lung biopsy. Although the surgical lung biopsy provides substantially more material for pathologic study, the procedure requires general anesthesia, and one or more days in the hospital with a chest tube in place. Moreover, there have been reports that this surgical procedure may be associated with excess mortality in certain disease states. For example, one study reported that 10 of 60 patients with usual interstitial pneumonia died within 30 days of the surgical lung biopsy.[23] In contrast, bronchoscopy can be done as an outpatient procedure, usually with minimal morbidity and mortality.[24] Even with the limited size of the biopsy specimen obtained with the bronchoscope, the clinician can often combine the information gained with other clinical, radiologic, microbiologic, and cytologic information to arrive at a diagnosis.

The main complication of TBB is bleeding; less frequent complications are pneumothorax, hypoxemia, or cardiac arrhythmias during the procedure. Bleeding occurs to some degree in virtually all TBB procedures and in some cases can be substantial. The risk of bleeding is the main limiting factor in obtaining more or larger biopsy samples. Bleeding is a major concern to the bronchoscopist because of the limited options available to manage excessive bleeding through the flexible bronchoscope. The suction channel of the typical bronchoscope is only 2 mm in diameter, and the volume of blood that can be suctioned through the channel is hence limited. One drop of blood can obscure the small lens of the bronchoscope and eliminate vision through the scope. Moreover, because the entire tracheobronchial tree is only about 150 mL in volume, a relatively small amount of blood can produce major problems with oxygenation.

Evaluation of the patient prior to the procedure is crucial. Even though inspection of the airways and possibly bronchoalveolar lavage can be done in patients with bleeding abnormalities or in those receiving anticoagulation therapy such as warfarin, TBB is contraindicated in the presence of bleeding abnormalities. An international normalized ratio (INR) greater than 1.5 is an absolute contraindication; successful TBB can be done if the INR is less than 1.5. If a patient is taking warfarin, it can usually be withheld for 4 to 5 days to allow the INR to slowly decrease to a safer range. If the warfarin cannot be withheld—for example, if the patient has a mechanical heart valve—then TBB will likely not be possible. Fresh-frozen plasma can be administered to reverse warfarin anticoagulation more quickly. Transbronchial biopsy is also contraindicated if the platelet count is less than 50 000/μL but the platelet count can be increased relatively quickly with platelet transfusions prior to the procedure. Also, platelet dysfunction is a relative contraindication to biopsy. There are insufficient data on antiplatelet agents such as clopidogrel, but most bronchoscopists are hesitant to perform a TBB if the patient is using this agent. Other contraindications for bronchoscopy and TBB are severe hypoxemia, uncontrolled cardiac arrythmias, unstable angina, and severe asthma or exacerbation of chronic obstructive pulmonary disease. The patient on mechanical ventilation support is at very high risk of pneumothorax, and TBB is not done in this circumstance, nor when extensive bullous disease, such as emphysema, is present.

In the hands of an experienced bronchoscopist, the procedure is quite tolerable for most patients. Following informed consent, conscious sedation is achieved, typically with a short-acting benzodiazepine and a narcotic, such as fentanyl or meperidine. A topical anesthetic, such a lidocaine, is applied to the upper airway mucosa. The bronchoscope can be passed through the nose or the mouth, depending on the preference of the bronchoscopist, and then through the vocal cords into the trachea. An endotracheal tube can be passed over the bronchoscope and into the trachea to achieve control of the airway. Topical lidocaine is administered to the bronchial mucosa during the procedure to reduce coughing. A complete endobronchial inspection of all segments of both lungs is performed to exclude significant endobronchial abnormalities. Often, bronchoalveolar lavage is obtained for culture and cytology specimens prior to the TBB.

The TBB is almost always done with fluoroscopic guidance as the rate of pneumothorax is reduced when fluoroscopy is used. The bronchoscope is directed to the segment desired for the biopsy and is wedged into that segmental bronchus as far as the scope will go. This ''wedge'' technique then isolates that segment in the case of bleeding, and also allows tamponade of that segment. Biopsy samples are then obtained repeatedly from this segment without removing the scope. A forceps is passed through the bronchoscope and into the segment as far as it will pass. The patient is asked to inhale and the forceps are opened. The patient is then asked to exhale and, at end-expiration, the forceps jaws are closed. If the patient experiences pain at this point, the forceps is opened and withdrawn because the only pain-sensitive structure in the area is the visceral pleura. Another location is selected. Approximately four to six biopsies are ideal (Figure 1). The bronchoscope is held in the wedge position until no further blood is visualized through the suction tubing. Biopsies from two different segments from the same lung can be obtained, but it is contraindicated to obtain biopsy specimens from both lungs because of concern for bilateral pneumothorax.

Transbronchial biopsies are obtained most commonly for the evaluation of mass lesions or localized infiltrates, in which neoplasm or infection leads the differential diagnosis. Patients with diffuse parenchymal lung disease (more than one lobe involved, and often bilateral abnormalities) undergo biopsy by this method, hoping to secure a definitive diagnosis, thus avoiding more invasive diagnostic procedures as discussed previously. Neoplasm and infection are still considerations when infiltrates are diffuse, but more often, inflammatory parenchymal disease is the primary clinical concern, and the TBB is the nonsurgical biopsy method of choice. The samples derived are typically only 2 to 3 mm in size but they hold a wealth of potentially useful information for the care of the patient.

A helpful general approach to the interpretation of the TBB is presented in Figure 2. Knowledge of the patient's immune status is an essential early key discriminator. For diffuse parenchymal diseases, histopathologic patterns of inflammatory disease are very helpful. Included in these patterns are (1) acute or subacute injury (infection, drug toxicity, systemic autoimmune disease); (2) chronic interstitial inflammation; (3) granulomatous inflammation and its differential diagnosis; (4) vascular diseases (including vasculitis/diffuse alveolar hemorrhage, pulmonary hypertension, and intravenous drug abuse microangiopathy); and (5) alveolar-filling processes such as alveolar proteinosis. In addition, rare distinctive lesions such as pulmo-

Downloaded from https://aplm.kglmeridian.com at 2026-03-06 via free access

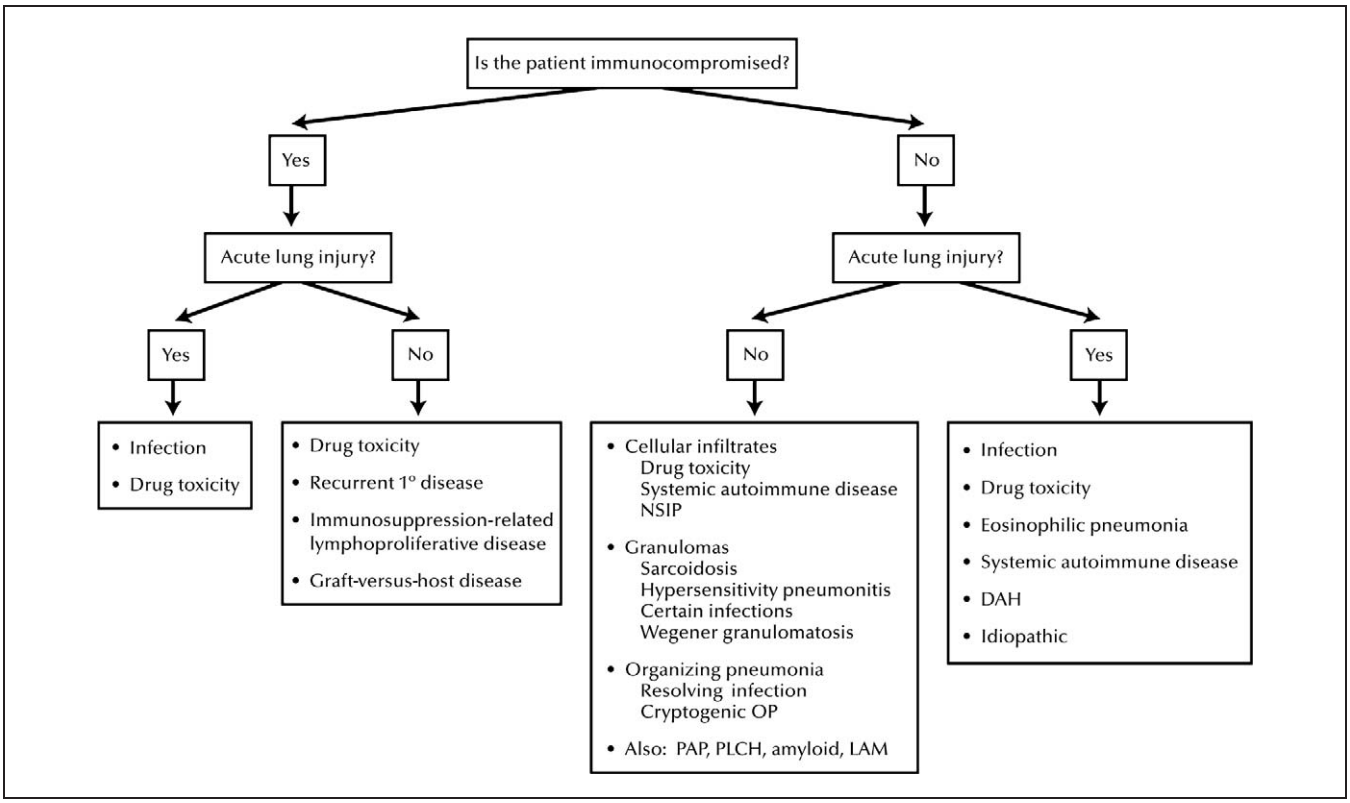

Figure 1. *The differential diagnosis for the transbronchial biopsy in the setting of diffuse lung disease depends highly on knowledge of the patient's immune status. NSIP, nonspecific interstitial pneumonia; OP, organizing pneumonia; PAP, pulmonary alveolar proteinosis; PLCH, pulmonary Langerhans cell histiocytosis; LAM, lymphangioleiomyomatosis; and DAH, diffuse alveolar hemorrhage.*

nary LCH, LAM, and alveolar microlithiasis are amenable to sampling by TBB.

In this article we will focus on 10 examples of useful histopathologic findings and specific diagnostic entities observable in TBBs in the setting of diffuse parenchymal disease. For specific named entities, we have provided some clinical and radiologic context. Localized neoplasms and transplant-related pathology will not be discussed because of space constraints.

USEFUL DIAGNOSTIC PATTERNS AND SPECIFIC ACHIEVABLE DIAGNOSES

Acute and Subacute Lung Injury

In the setting of acute onset lung disease, infection always leads the differential diagnosis, and the TBB, bronchial washings, and bronchoalveolar lavage play a crucial role in the clinical evaluation. Computed tomographic scans typically show ground-glass attenuation and consolidation to a variable degree, although the imaging does not discriminate between edema, acute injury, or hemorrhage (see ''Immunologically Mediated Diffuse Alveolar Hemorrhage'' for a CT image of acute infiltrates in Goodpasture syndrome). Both acute and subacute lung injury are grouped under one heading in this article because they often occur together (areas of acute injury adjacent to areas of early repair with fibroblasts in the alveolar spaces). When fibrin, hyaline membranes, and/or organization in alveolar spaces are identified, the differential diagnosis is always the same: infection, drug toxicity, systemic connective tissue diseases manifesting in the lung, and idiopathic forms.[25,26] The potential causes of acute lung injury with hyaline membranes (diffuse alveolar damage) are presented in Table 1.

Special stains for organisms must be performed on any TBB that has more than a microscopic focus of fibrin in the alveolar spaces, hyaline membranes, or necrosis without evident neoplasm. Acid-fast and silver stains (Fite acid-fast and Grocott methenamine silver) should always be performed when fibrin or granulomas are present in a TBB. When necrosis is seen in the context of acute clinical disease, the battery of stains should be extended to include a tissue Gram stain and at least one special silver impregnation technique (Warthin-Starry or Dieterle). These latter techniques will stain some organisms that can be negative on acid-fast, silver, and Gram stains and, furthermore, tend to make bacteria more visible even when the Gram stain is positive. Keep in mind that the clinical management in the acute care setting aggressively targets infection before a biopsy is performed and it is unusual for the pathologist to be the first to discover bacterial infection as a cause of acute clinical disease. The most common unexpected infection diagnosed in our consult practice is *Pneumocystis* pneumonia, typically occurring in the mild-to-moderately immunocompromised host (often iatrogenic immunocompromise). *Coccidioides*, *Aspergillus*, *Nocardia*, *Actinomyces*, *Histoplasma*, *Blastomyces*, herpes simplex, and Cytomegalovirus are also identified on occasion. Rarely, we see fastidious organisms such as *Legionella* as a cause of acute suppurative bronchopneumonia before microbiological cultures have identified the organism (for a variety of reasons).

Once bacterial, fungal, and mycobacterial infections

Downloaded from https://aplm.kglmeridian.com at 2026-03-06 via free access

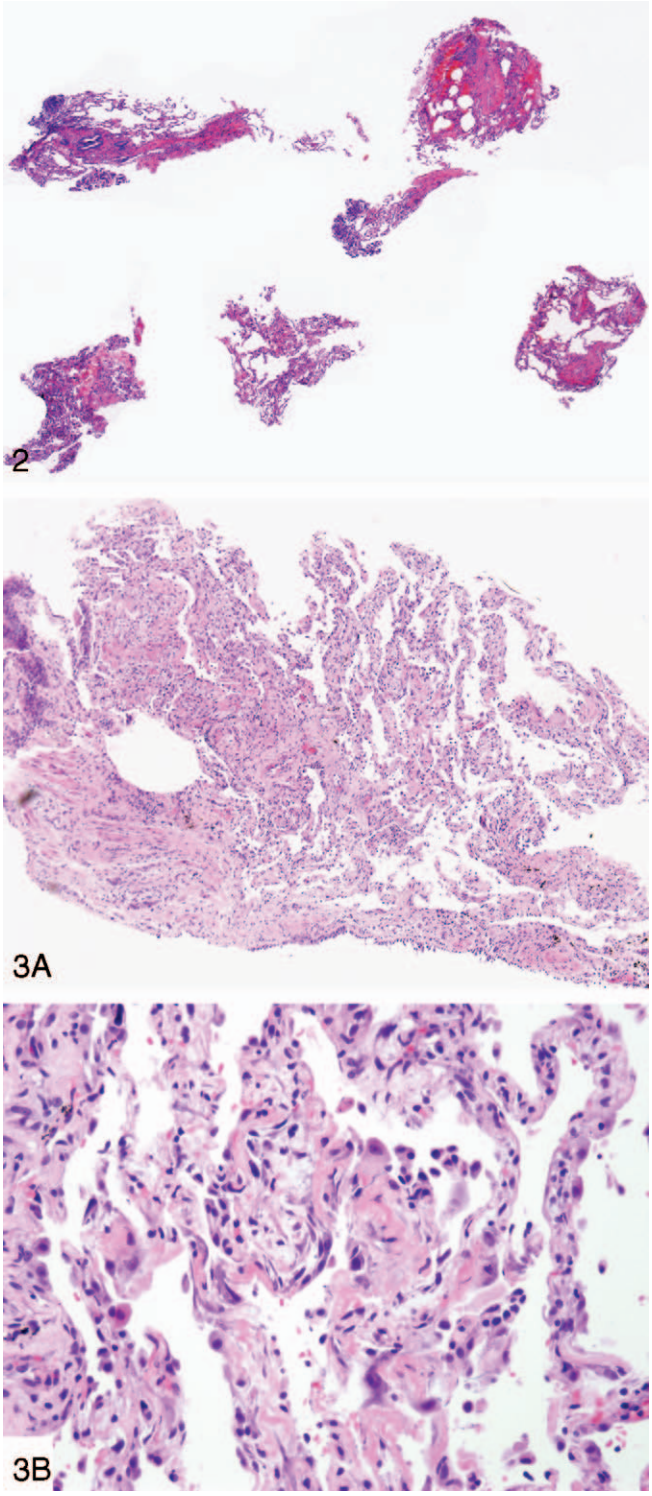

Figure 2. *The ideal transbronchial biopsy. Six generous alveolar parenchymal biopsies are illustrated here, although this number of entirely alveolar samples is exceptional. Biopsy size is most often in the range of 2 to 3 mm. Typically, one or more biopsies in any set will consist entirely of bronchial mucosa likely derived from a minor carina (this is recognizable by the presence of cartilage). In the setting of diffuse parenchymal disease, it is helpful to include in the diagnosis the number and quality of alveolar parenchymal fragments evaluated (hematoxylin-eosin, original magnification ×20).*

Figure 3. *Diffuse alveolar damage (DAD). A, Acute lung injury with hyaline membranes has an overall eosinophilic appearance at scanning magnification. Alveolar walls are thickened by fibrin, edema, and mild cellularity early in the process. Alveolar spaces may contain immature fibroblasts (myofibroblasts) to varying degree. By convention, the diagnosis of DAD requires the presence of hyaline membranes (even "organizing DAD"). When edema and fibrin are present (typically accompanied by reactive type 2 cell hyperplasia), but hyaline membranes are absent, a descriptive diagnosis is appropriate (eg, "acute lung injury with airspace fibrin/organization") (hematoxylin-eosin, original magnification ×40). B, At higher magnification hyaline membranes are easily identified. Whenever airspace fibrin and/or hyaline membranes are present, special stains for organisms should be performed to exclude infection (hematoxylin-eosin, original magnification ×200).*

Table 1. Conditions Most Commonly Associated With Diffuse Alveolar Damage

Shock
Infections (viral, fungal, bacterial, parasitic)
Toxic inhalants
Acute allergic reactions (eg, hypersensitivity pneumonitis)
Drug reactions
Systemic collagen vascular diseases
Radiation reactions (acute)
Alveolar hemorrhage syndromes
Idiopathic disease (acute interstitial pneumonia)

have been reasonably excluded, a careful search for viral cytopathic changes is warranted, mainly if the patient is known to be immunocompromised and especially if necrosis is present. In our experience, in the absence of necrosis in the specimen, we rarely confirm a viral cause for a given acute process. Caution must be taken in regard to "pseudoviropathic" changes, such as large reactive nucleoli or globular cytoplasmic debris that can be seen in many acute inflammatory conditions.

As mentioned previously, the two other detectable causes of acute lung injury include toxic reaction to drug[27] and acute manifestations of systemic autoimmune diseases.[28] Regarding drug-related injury, no histopathologic changes are specific for any drug, despite any claims in the literature to the contrary. Identifying a direct relationship between initiation of a drug and onset of clinical symptoms is essential. For drugs commonly known to produce lung injury as a side effect (eg, amiodarone), unexplained acute injury of noninfectious origin must be considered as drug-related until proven otherwise. Every named rheumatic disease (except Sjögren syndrome) has been implicated as a cause of acute injury in the lung.[28–30] Moreover, acute lung injury may be the initial manifestation in a subset of rheumatic diseases (eg, polymyositis/dermatomyositis[31,32]), so this is worth keeping in mind.

Depending on when the biopsies are performed relative to onset of symptoms, acute lung injury patterns may be dominated by organizing pneumonia in the TBB. Potential causes of the organizing pneumonia pattern are presented in Table 2. In this setting it is tempting to refer to this pathologically as bronchiolitis obliterans organizing pneumonia. We would discourage this because, to our clinical colleagues, this name implies idiopathic bronchiolitis obliterans organizing pneumonia, a disease that is expected to respond to corticosteroid therapy.[33–35] Clearly, many causes of organizing pneumonia may be resistant to corticosteroid therapy. The term *airspace organization* or *organizing pneumonia pattern* is preferable as a more accurate descriptor of this phenomenon. When airspace organiza-

Downloaded from https://aplm.kglmeridian.com at 2026-03-06 via free access

Table 2. Common Causes of the Organizing Pneumonia Pattern
Organizing infections (any cause)
Organizing diffuse alveolar damage
Hypersensitivity pneumonitis
Aspiration pneumonia
Eosinophilic pneumonia
Drug and toxin reactions
Systemic collagen vascular diseases
Cryptogenic organizing pneumonia
Peripheral reaction around focal lesions
Abscesses
Infarcts
Wegener granulomatosis
Malignant tumors

tion is accompanied by nodular aggregations of fibrin in the alveolar spaces (but no hyaline membranes), the term *acute fibrinous and organizing pneumonia* is appropriate, as long as it is recognized that this diagnosis as an idiopathic condition has a guarded prognosis if the patient requires mechanical ventilation around the time of biopsy.[36] Also, idiopathic diffuse alveolar damage (referred to clinically as *acute interstitial pneumonia*) may be a manifestation of the adult respiratory distress syndrome in the setting of a ventilator-dependent patient. Given the appropriate clinical scenario and time course, no further cause for this histopathologic finding need be sought by the clinician. Many of the acute lung injury histopathologic changes are recapitulated in acute eosinophilic pneumonia and diffuse alveolar hemorrhage (see later discussion). A diagnostic TBB in diffuse alveolar damage is presented in Figure 3, A and B.

Eosinophilic Pneumonia

Clinical Scenario.—Eosinophilic pneumonia encompasses a number of disorders centered around increased eosinophils in lung parenchyma. The original description of ''pulmonary eosinophilia'' in 16 patients reported by Crofton and colleagues[37] proposed a classification to include simple pulmonary eosinophilia (few symptoms and transient infiltrates), prolonged pulmonary eosinophilia with persistent radiographic shadows persisting for more than a month (and sometimes other organ involvement), tropical eosinophilia, and pulmonary eosinophilia in the setting of asthma. In 1969, Liebow and Carrington[38] questioned the value of this mainly clinical classification and proposed that all eosinophilic pneumonia be described in relation to an etiology whenever possible (eg, eosinophilic pneumonia related to helminthic infestation or eosinophilic pneumonia induced by chemical agents). An excellent overview of eosinophilic lung disease can be found in a 1994 review by Allen and Davis.[39]

The most common pulmonary symptom is dyspnea, which can be severe. In acute forms, the condition has sudden onset, and clinical presentation is generally immediate.[40] Without a bronchoscopic diagnosis, acute eosinophilic pneumonia is frequently mistakenly treated as an infectious pneumonia, needless to say without success. In chronic forms, evolution during weeks to a few months is common and breathlessness is less severe. Night sweats with fever and chills occur to variable extent. Peripheral blood eosinophilia as well as increased eosinophil counts in pulmonary lavage samples are useful diagnostic findings, but may not be identified for a variety of reasons.

Table 3. Potential Causes of Lung Tissue Eosinophils
Asthma
Drug reaction
Some fungal infections (eg, coccidiodomycosis)
Parasitic infestation
Acute eosinophilic pneumonia (idiopathic)
Churg-Strauss syndrome
Hypereosinophilia syndromes
Cigarette smoking

Radiologic Findings.—Peripheral consolidation is the most common appearance of eosinophilic pneumonia, whether idiopathic or related to a known antigen. Minimal architectural distortion, such as traction bronchiolectasis and lobular distortion in the areas of the consolidation, can occur in chronic cases. Areas of consolidation are most common in the middle and lower zones and are frequently bilateral. Although the distribution can be peribronchovascular, this is not a consistent finding.[41] If the distribution is peripheral and nonsegmental, TBB is less likely to be diagnostic.

The radiographic differential diagnosis typically includes infection in acute cases and cryptogenic organizing pneumonia in the more subacute or chronic course. Acute eosinophilic pneumonia is exquisitely steroid-responsive and areas of consolidation often resolve within 24 hours of treatment. A trial of steroids, without the need for a tissue sample, is most common in patients in whom a bronchoscopic lavage was negative for infection by direct smear and culture. Transbronchial biopsy (and surgical biopsy), therefore, is more commonly performed in patients with a subacute or chronic presentation in whom steroid responsiveness is less dramatic and the diagnosis is less certain clinically.

Bronchoscopic Approach.—In the patient with unexplained pulmonary infiltrates, especially if migratory, bronchoalveolar lavage with a differential cell count is an important adjunct to the diagnosis. Transbronchial biopsies are diagnostic in most cases if one or more infiltrates is sampled.

Histopathology.—Eosinophilic pneumonia is a histopathologic subtype of acute lung injury. Eosinophilic pneumonia is characterized by the triad of reactive type 2 cell hyperplasia, eosinophils free in the alveolar spaces accompanied by densely eosinophilic macrophages, and variable amounts of fibrin.[38,40] The differential diagnosis of increased tissue eosinophils in the lung is presented in Table 3. Sometimes the tissue eosinophils are sufficiently pronounced so that eosinophilic microabscesses can be seen. Also, the dense eosinophilic macrophages tend to aggregate and produce ''pseudogranulomas'' in the alveolar spaces. In the TBB, eosinophilic pneumonia is easily diagnosable when the requisite features are present. A differential diagnosis is always appropriate for eosinophilic pneumonia, recognizing that this can occur as a consequence of certain infections (particularly fungal infections such as coccidioidomycosis), as a manifestation of asthma, in allergic bronchopulmonary fungal disease (again, most commonly in asthma), and as a consequence of drug toxicity. Unfortunately, not all patients with eosinophilic pneumonia will recover, despite corticosteroid administration. Also, whether acute or chronic, the histopathology

Downloaded from https://aplm.kglmeridian.com at 2026-03-06 via free access

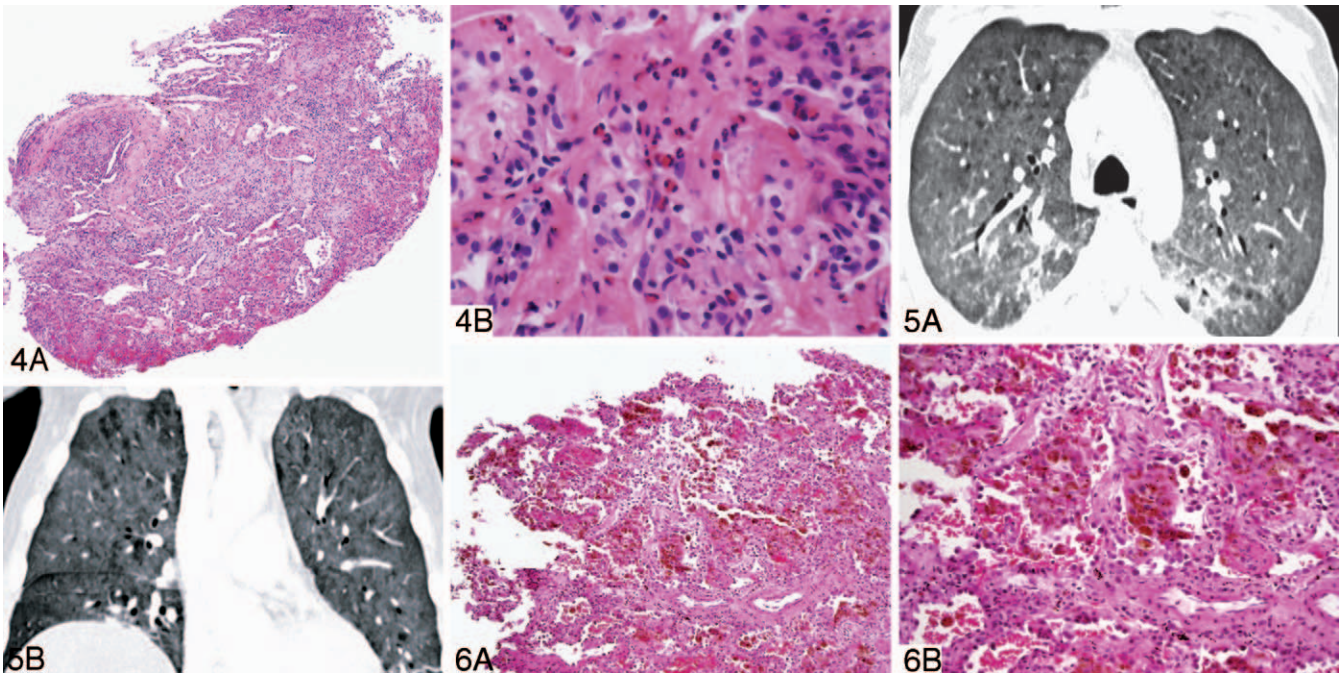

Figure 4. *Acute eosinophilic pneumonia. A, At scanning magnification, the alveolar parenchyma is consolidated by intra-alveolar fibrin, macrophages, and eosinophils. The macrophage accumulation may be accompanied by multinucleated giant cells (hematoxylin-eosin, original magnification ×40). B, The diagnosis of eosinophilic pneumonia (acute or "chronic") requires the triumvirate of densely eosinophilic macrophages, fibrin, and eosinophils, all within the alveolar spaces. Markedly reactive type 2 cells are an expected finding. Varying amount of organizing pneumonia may be present. Eosinophilic vasculitis and eosinophilic microabscesses are not prerequisites for the diagnosis. The dense and cohesive nature of the intra-alveolar macrophages in eosinophilic pneumonia sometimes suggests granulomas, especially when multinucleated giant cells are present. The accompanying eosinophils would be unexpected in most cases of granulomatous infection (hematoxylin-eosin, original magnification ×200).*

Figure 5. *Pulmonary hemorrhage in Goodpasture syndrome. A, Axial computed tomographic (CT) image shows extensive ground-glass opacity throughout both lungs without pulmonary venous distension or architectural distortion. There is a vague rim of cortical sparing, common in pulmonary hemorrhage and edema, related to the clearing of blood or fluid via the well-developed peripheral lymphatic system. B, The CT image reformatted in the coronal plane shows extensive ground-glass attenuation throughout both lungs and the relative sparing of the outer zone of both lungs. The pulmonary vessels are normal in caliber and there is no architectural distortion.*

Figure 6. *Diffuse alveolar hemorrhage in Goodpasture syndrome. A, Diffuse alveolar hemorrhage of immunologic origin has similar histopathologic features regardless of the specific serologic context of the process. At scanning magnification, the biopsies appear red or red-brown, depending on the degree of hemosiderosis present. It is best not to diagnose alveolar hemorrhage in the absence of siderophages (to be distinguished from smokers' macrophages) and some intra-alveolar aggregated fibrin (hematoxylin-eosin, original magnification ×40). B, At higher magnification, all of the necessary features of true alveolar hemorrhage are present: fresh blood, fibrin, siderophages, reactive type 2 cells, and some evidence of organization (this varies considerably). In this example, the patient had hemoptysis, anemia, and renal disease, with antiglomerular basement membrane antibodies in serum. Importantly, capillaritis and necrotizing vasculitis may not be present (hematoxylin-eosin, original magnification ×200).*

is similar. A diagnostic TBB in eosinophilic pneumonia is presented in Figure 4, A and B.

Immunologically Mediated Diffuse Alveolar Hemorrhage

Diffuse alveolar hemorrhage of immunologic origin can be diagnosed with the bronchoscope when the TBB shows hemosiderin-laden macrophages in alveolar spaces, fibrin admixed with siderophages, and organizing pneumonia.[42] Capillaritis or necrotizing vasculitis may be seen in this context and, as these findings may be harbingers of catastrophic hemorrhage, immediate notification of the clinician is imperative. Clinical context is essential. The patient typically presents with hemoptysis or anemia and the bronchoscopist will often describe the lavage samples as becoming progressively pink or red. The CT scan shows ground-glass attenuation and consolidation (Figure 5, A and B). Positional maneuvers may result in a change in distribution of the infiltrates (this also occurs for edema).

Without capillaritis or necrotizing vasculitis, the findings of pigment-laden macrophages accompanied by fibrin are less specific for immune-mediated hemorrhage, and a compelling clinical history is necessary (hemoptysis with positive serologic studies; see later discussion). In our consult practice, we diagnose cases showing good hemosiderosis, fresh alveolar hemorrhage, fibrin, and organization as "acute and organizing pulmonary hemorrhage consistent with immune-mediated diffuse alveolar hemorrhage (microscopic polyangiitis, Wegener granulomatosis, Goodpasture syndrome, systemic connective tissue disease, and drug toxicity are in the differential diagnosis)" and recommend serologic testing. Serologic studies (eg, antinuclear antibody, antineutrophil cytoplasmic autoantibody, antiglomerular basement membrane antibodies) are the preferred mode of confirming the diagnosis for purposes of therapy. We do not perform or recommend immunofluorescence studies on lung biopsies to support or refute a diagnosis of immune-mediated pulmonary hemorrhage, given the reliability of serologic studies and the technical challenges presented by diagnostic immunofluorescence in the lung.[43] Potential causes of diffuse

Downloaded from https://aplm.kglmeridian.com at 2026-03-06 via free access

Table 4. Causes of Diffuse Alveolar Hemorrhage
Goodpasture syndrome (antiglomerular basement membrane antibody disease)
Vasculitides (especially Wegener granulomatosis)
Mitral stenosis
Bronchiectasis (often unilateral, or unilobar)
Immunoglobulin A nephropathy
Behcet syndrome
Certain systemic collagen vascular diseases (especially systemic lupus erythematosus)
Antiphospholipid syndrome
Human immunodeficiency virus infection
Pulmonary veno-occlusive disease
Idiopathic pulmonary hemosiderosis
Drug reactions, including toxic reactions and anticoagulants
Acute lung allograft rejection
Isolated capillaritis

alveolar hemorrhage are presented in Table 4. A diagnostic TBB in Goodpasture syndrome is presented in Figure 6, A and B.

Chronic Inflammation (Chronic Cellular Infiltrates)

The significance of chronic inflammation in the bronchoscopic biopsy depends largely on location of the inflammatory cells relative to the microanatomy of the sample. Sometimes the specimens received are entirely bronchial mucosa. Chronic inflammation of mild degree is a common nonspecific finding in this setting, especially in smokers. The same amount of chronic inflammation in a biopsy consisting entirely of alveolar parenchyma would be significant and would raise a differential diagnosis to include hypersensitivity pneumonitis (even without visible interstitial granulomas), low-grade infection, chronic drug reaction, systemic connective tissue disease manifesting in the lung, and so-called nonspecific interstitial pneumonia.[44] Naturally, this differential diagnosis presupposes that the patient has diffuse infiltrates on radiologic imaging. Conditions associated with chronic inflammation in alveolar walls (cellular interstitial infiltrates) are presented in Table 5.

For the group of diseases in the differential diagnosis of cellular interstitial infiltrates, the clinical presentation is typically subacute to chronic (weeks to months in evolution). Computed tomographic studies most often are dominated by ground-glass opacification (hazy increased attenuation with airways and arteries still visible through it). When the correct diagnosis is subacute hypersensitivity pneumonitis, fuzzy centrilobular nodules are present with a very suggestive appearance[22,45] (Figure 7, A and B). In such cases, TBBs may be diagnostic. The CT findings in subacute hypersensitivity pneumonitis are quite different than the findings in patients with nonspecific interstitial pneumonia or usual interstitial pneumonia or even chronic hypersensitivity pneumonitis. Also, chronic hypersensitivity pneumonitis is less likely to be confidently diagnosed with TBB. Patients with fibrotic lung disease that is not central or peribronchovascular should not have the procedure.

The TBB in subacute hypersensitivity pneumonitis typically shows airway mucosal chronic inflammation, either as subepithelial infiltration or lymphoid aggregates. Alveolar parenchymal samples will show increased numbers of lymphocytes and plasma cells involving the alveolar walls. Multinucleated giant cells with calcified bodies

Table 5. Lung Diseases With Chronic Inflammatory Interstitial Infiltrates
Resolving infection
Hypersensitivity pneumonitis
Systemic collagen vascular diseases manifesting in the lung
Certain toxic or hypersensitivity drug reactions
Nonspecific interstitial pneumonia
Lymphoid interstitial pneumonia (idiopathic type)
Lymphocytic interstitial pneumonia in human immunodeficiency virus infection
Lymphoproliferative diseases (typically low grade)

(Schaumann bodies) may be seen beneath the bronchial mucosa, but this is a nonspecific finding. If small nonnecrotizing interstitial granulomas are also present, a more confident diagnosis of hypersensitivity pneumonitis can be made.[46–49] Tiny patches of organizing pneumonia are commonly present in hypersensitivity pneumonitis and other conditions in this category. If a diffuse lymphoid infiltrate of considerable density is present, low-grade lymphoma enters the differential diagnosis, similar to the classic diagnosis of lymphoid interstitial pneumonia. Other common findings when hypersensitivity pneumonitis is in the differential include prominent airspace macrophages with foamy cytoplasm. A diagnostic TBB in subacute hypersensitivity pneumonitis is presented in Figure 8, A and B.

Sarcoidosis

Clinical Scenario.—Sarcoidosis is a chronic multisystem granulomatous disorder of unknown etiology characterized by the formation of granulomas composed of epithelioid histocytes. Different from infectious granulomas, the granulomas of sarcoidosis typically lack necrosis. Virtually any organ with lymphatics can be affected by the granulomatous inflammation of sarcoidosis, although lung, upper respiratory tract, lymph nodes, eye, and skin dominate the presentation. The peak incidence of the disease is young adulthood, with women affected more than men. African Americans, Asians, and Scandinavians have historically been considered to be at greater risk for developing sarcoidosis, but it is unclear how the previously reported incidence in these groups is related to genetic, geographic, socioeconomic, environmental, or differential access to medical care factors.[50–52]

General clinical manifestations include malaise, fatigue, fever, and weight loss in about one third of patients. Pulmonary symptoms include vague chest discomfort, to dyspnea on exertion and cough. Often the patient is entirely asymptomatic and the diagnosis becomes suspected from a chest radiograph or CT scan performed for some other reason. Upper respiratory tract involvement is characterized by nasal stuffiness and nasal blockage. Skin involvement in sarcoidosis is manifested most commonly by erythema nodosum (nodular panniculitis) and lupus pernio

Table 6. Diffuse Diseases Associated With Nodular Granulomatous Inflammation
Sarcoidosis
Granulomatous infections
Intravenous talcosis
Pneumoconioses (eg, inhalation talcosis, berylliosis)
Aspiration pneumonia
Wegener granulomatosis

Downloaded from https://aplm.kglmeridian.com at 2026-03-06 via free access

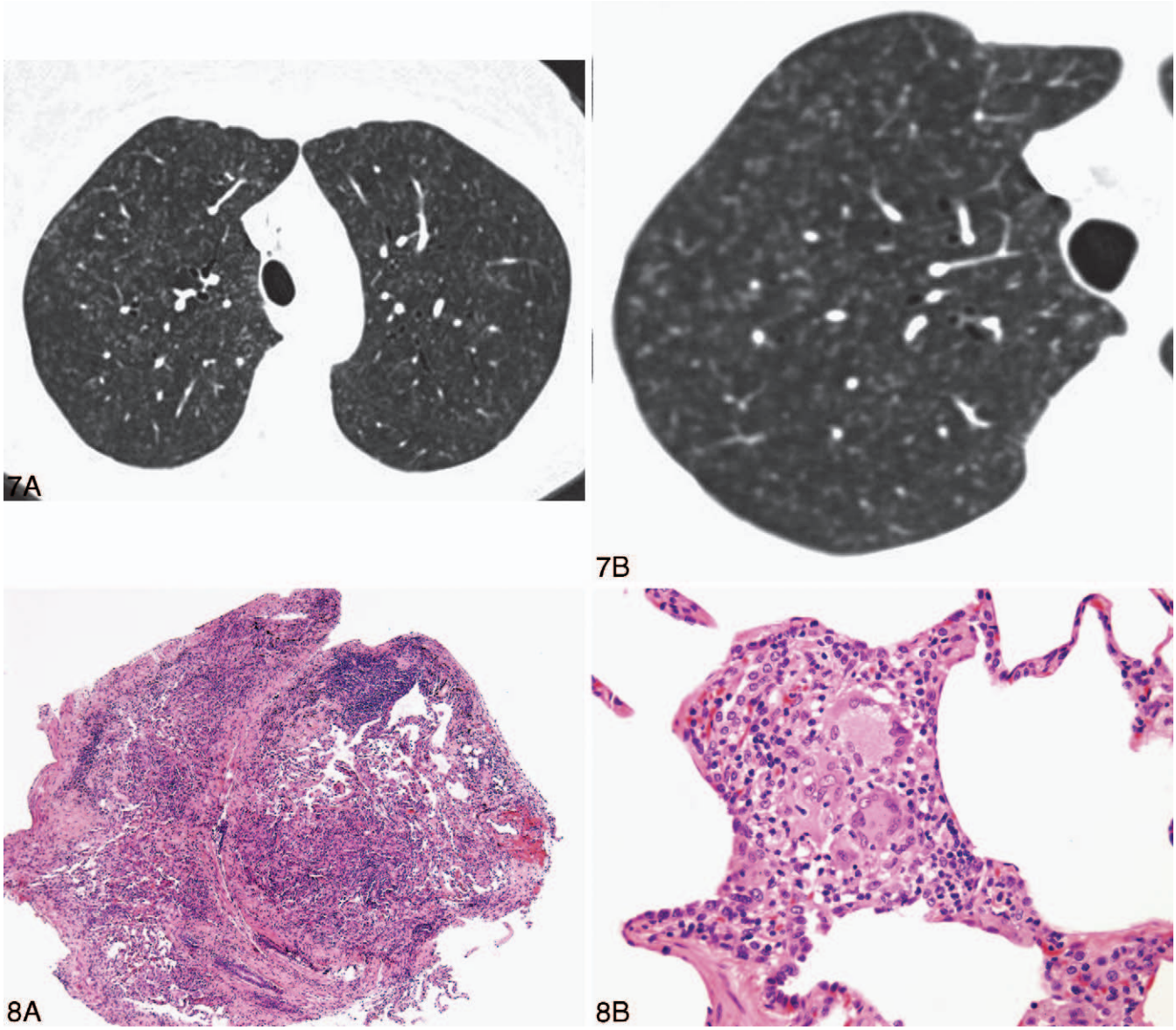

Figure 7. *Hypersensitivity pneumonitis. A, Axial computed tomographic (CT) image shows innumerable nodules of ground-glass attenuation, particularly in the upper lungs. These small fuzzy nodules are centered on the visible dotlike outlines of the pulmonary arteries in cross section, and are therefore centrilobular in location. This appearance is characteristic of hypersensitivity pneumonitis, but only in the subacute stage. B, Magnified axial CT image of the right upper lobe clearly shows the fuzzy ground-glass attenuation nodules with dense arterial branches in the center of the lesions. Note that the nodules spare the peripheral pleural surfaces, another feature characteristic of centrilobular disease.*

Figure 8. *A, Also referred to as "extrinsic allergic alveolitis," hypersensitivity pneumonitis is a recognizable subtype of chronic cellular interstitial disease. In all of the conditions included in this category of inflammatory lung disease, lymphocytes and plasma cells often dominate the infiltrate, imparting a more or less "blue" appearance to the biopsy at scanning magnification (hematoxylin-eosin, original magnification ×40). B, When cellular chronic infiltrates are present, a careful search for granulomas is always in order. Here, a poorly formed granuloma is present in the interstitium, a characteristic feature of hypersensitivity pneumonitis. This patient had a pet bird (hematoxylin-eosin, original magnification ×200).*

(violaceous papules and plaques). For a comprehensive review of sarcoidosis, the reader is referred to the joint statement of the American Thoracic Society, the European Respiratory Society, and the World Association of Sarcoidosis and other Granulomatous Disorders.[53] Potential causes of nodular granulomatous inflammation are presented in Table 6.

Radiologic Findings.—The CT findings in sarcoidosis reflect the stage of the disease.[54,55] Early parenchymal findings reflect granulomatous inflammation in the axial and, to a lesser extent, peripheral and subfissural interstitium. A CT scan at this stage shows multiple, well-defined, tiny nodules with a middle and upper posterior lung predominance (Figure 9, A through D). Lymph node enlargement is variable and is not helpful in the differential diagnosis. Computed tomography is often diagnostic in such instances in the proper clinical context, but if tissue diagnosis is required, TBB has a yield approaching 100%. It should be noted that a normal CT does not exclude the diagnosis, and TBB can be positive in patients with a normal CT.

As the parenchymal findings evolve, increasing masslike fibrosis occurs with architectural distortion and volume loss, especially in the posterior upper lung zones, often with paracicatricial emphysema (Figure 9, C and D). Nodules at this

Downloaded from https://aplm.kglmeridian.com at 2026-03-06 via free access

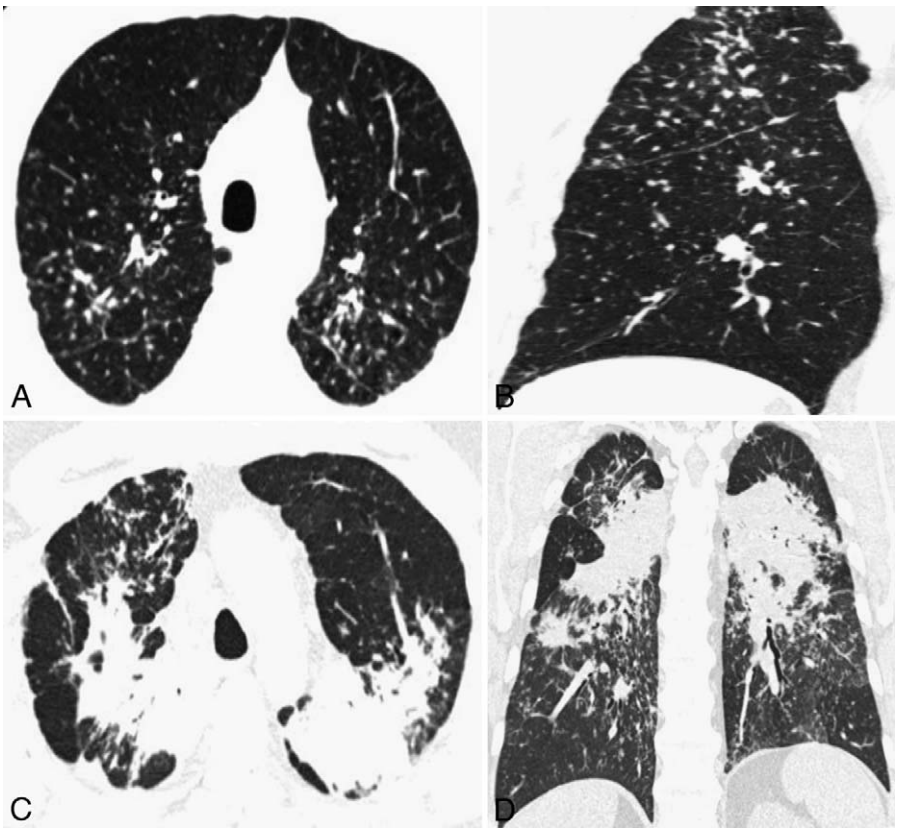

Figure 9. *A and B, Nodular sarcoidosis. A, Axial computed tomographic (CT) image shows well-defined small nodules with profusion in the posterior portion of the upper lobes. Note the beading of the pleural and fissural surfaces (peripheral interstitial involvement) and the beaded bronchoarterial branches (axial interstitial disease). B, Coronal reformatted CT image of the right lung shows the nodules in the upper lung and prominent beading of the oblique fissure. C and D, Chronic sarcoidosis with fibrosis. C, Axial CT image shows large dense masses in the posterior portion of both upper lobes with peripheral areas of persistent tiny nodules especially on the right. These masses are perihilar and associated with significant architectural distortion and local volume loss. D, CT image in the coronal plane shows the large perihilar masses with distortion and the extensive low density paracicatricial emphysema [sic] related to peripheral air trapping caused by the extensive fibrosis in the axial interstitium.*

stage often are not present. Pulmonary hypertension may be evident. The CT findings often suggest the diagnosis, although TBB at this stage may be nonspecific.[56]

Bronchoscopic Approach.—The flexible bronchoscope is the mainstay of diagnosis, given the high incidence of pulmonary involvement in the disease. A high degree of diagnostic accuracy is achieved if more than 4 samples are taken. The distribution of granulomas along pulmonary lymphatic routes makes this possible because lymphatics travel along the bronchovascular bundles and are copiously sampled in the TBB specimen. Airway sarcoidosis should be suspected in patients with intractable cough. In this context, the lesions are often visible to the bronchoscopist as nodules or raised plaques and can be sampled directly with the cupped forceps. Transbronchial biopsy in sarcoidosis is especially important because diagnostic granulomas may be present even when the chest radiographs and CT scans fail to reveal lung parenchymal disease.

Histopathology.—Bronchoscopic biopsies are commonly used for a diagnosis of sarcoidosis in the appropriate clinical and radiologic context.[9,57,58] Multiple biopsies increase the likelihood of obtaining a diagnosis. The salient histopathologic features are well-formed nonnecrotizing granulomas, typically occurring as small confluences within hyalinized connective tissue. Minimal chronic inflammation may be present, but an alternate diagnosis is appropriate when abundant chronic inflammation is seen and granulomas are less well formed.[59] These latter changes typically herald low-grade infection, aspiration pneumonia, or hypersensitivity pneumonitis.

As an illustration of the problem of distinguishing sarcoid granulomas from those of infection in small tissue samples, Hsu et al[58] studied 92 cases in which granulomas were identified on TBB, but special stains on tissue sections were negative for organisms. In 83 of these cases, interstitial lung disease was present clinically and sarcoidosis was being considered. Subsequent microbiological cultures from tissue samples obtained at the initial bronchoscopy (cultures were obtained for all 92 cases), showed positive results in 10 (9 mycobacterial and 1 fungal), and these ultimately were diagnosed as granulomatous infection. The remaining cases were classified as sarcoidosis. Necrosis in the granulomas was observed in 20% of the cases of sarcoidosis, but in only 40% of the infectious cases. Interestingly, the granulomas in sarcoidosis tended to be present in greater number than those seen in the infectious cases. In this study, Schaumann bodies were also more likely to be present in association with sarcoidosis.

Unfortunately, the granulomas of sarcoidosis seen in bronchial mucosal biopsies may be less distinct than those seen in the lymph nodes or lung parenchyma. When the features are not compelling for the diagnosis (''naked'' granulomas aggregated within dense sclerotic collagen), a broader differential is always appropriate.[59] Moreover, berylliosis can produce histopathologic changes identical to those of sarcoidosis,[60] so it is appropriate to include berylliosis in the differential diagnosis of sarcoidosis. A diagnostic TBB in sarcoidosis is presented in Figure 10, A and B.

Wegener Granulomatosis

Clinical Scenario.—Wegener granulomatosis (WG) is a multisystem disorder characterized by distinctive necrotizing granulomatous inflammation involving the upper and lower respiratory tract, generalized necrotizing vasculitis involving small arteries and veins, and renal disease in the form of necrotizing glomerulonephritis.[61,62] Limited forms may have only upper and lower respiratory tract pathology.

Downloaded from https://aplm.kglmeridian.com at 2026-03-06 via free access

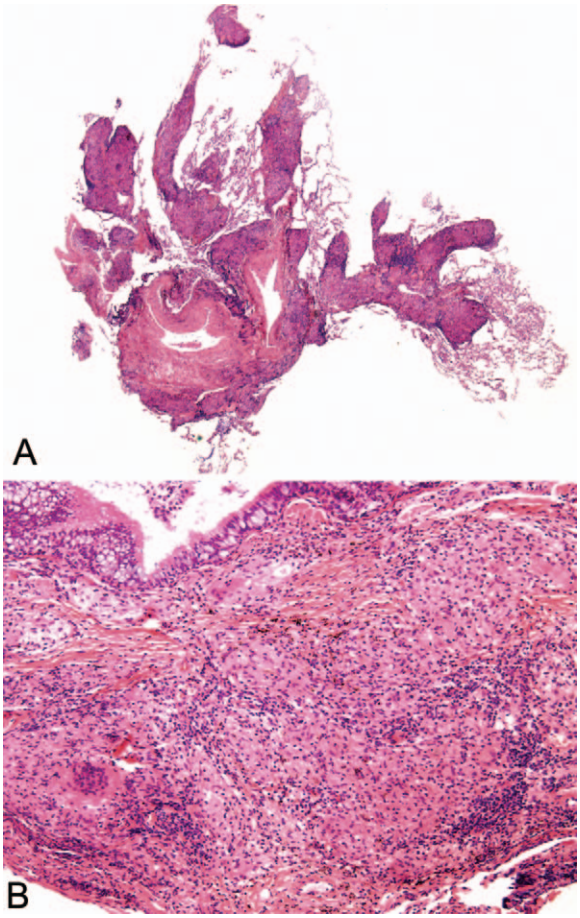

Figure 10. *Sarcoidosis. A, At scanning magnification, coalescent nonnecrotizing granulomas are present in this transbronchial biopsy from a patient with sarcoidosis. Note the serpiginous appearance of the infiltrate, corresponding to granulomas tracking along lymphatics in the specimen (hematoxylin-eosin, original magnification ×40). B, Granulomas are one of the most recognizable histopathologic findings in anatomic pathology. The trick is distinguishing which granulomas are a product of infection and which are the result of noninfectious immune disorders and reactions. The granulomas illustrated here are nonnecrotizing and present beneath the bronchial epithelium. Note the associated chronic inflammatory cells. When hyaline fibrosis surrounds the granulomas, the diagnosis of sarcoidosis is more likely. In a case such as this one, once acid-fast and silver stains are negative, a diagnosis of nonnecrotizing granulomas consistent with sarcoidosis/berylliosis is given. Despite negative special stains for organisms, infection (or other etiology) cannot be entirely excluded. Clinical correlation is required (hematoxylin-eosin, original magnification ×200).*

Patients with lung disease (infiltrates or nodules) typically have pre-existing disease in the sinonasal region. Intranasal manifestations include thick mucosal crusts, septal perforation, and chondritis resulting in saddle deformity. A wide variety of ophthalmic manifestations are also well described, including uveitis, corneoscleral ulceration, and lacrimal duct damage. Pulmonary manifestations are varied and include acute onset shortness of breath and acute hemoptysis.[63] Serologic studies most frequently show antineutrophilic cytoplasmic antibodies of cytoplasmic type with reaction against proteinase 3.

Radiologic Findings.—There are no CT findings that are specific for WG. The most common CT appearance in patients who undergo TBB is that of multiple nodules, typically ill-defined, peribronchovascular, and often cavitary.[64] Endobronchial or endotracheal lesions may also occur. The differential diagnosis usually includes sarcoidosis (if no cavities are present) and infectious granulomatous disease. The association of peribronchovascular nodular consolidation with or without cavitation (Figure 11) in a patient with sinusitis or renal failure suggests the diagnosis, and if renal disease is present clinically, such patients often undergo renal sampling rather than TBB.

Bronchoscopic Approach.—Endobronchial biopsy may show perichondritis and mixed inflammatory infiltration, including lymphocytes, plasma cells, and eosinophils.[65] Cartilage destruction can result in catastrophic airway collapse. Transbronchial biopsies are useful when collagen microabscesses are present in a background of dense mixed inflammatory infiltration, with or without perichondritis (see later discussion).

Histopathology.—Bronchial mucosal biopsies and TBBs can be diagnostic of WG, but the diagnosis requires considerable experience with the histopathologic manifestations of this disease.[66,67] Moreover, WG has a wide range of histopathologic manifestations, complicating further an accurate diagnosis in the limited biopsy sample obtained with the bronchoscope. In classic nodular WG, multiple bilateral nodules are the norm, often with some cavitation. In contrast, infectious granulomas are frequently solitary or localized. In the alveolar hemorrhage form of WG, acute and organizing pulmonary hemorrhage dominates the histopathology, often with prominent capillaritis. Organizing pneumonia can be the dominant appearance of WG in the so-called bronchiolitis obliterans organizing pneumonia-pattern WG.

As mentioned previously, the key findings that should suggest a diagnosis of WG are a dense mixed inflammatory infiltrate (including lymphocytes, plasma cells, and eosinophils), microscopic foci of collagen necrosis (with or without histiocytic palisading), perichondritis, capillaritis, hemosiderosis, and isolated osteoclast-like giant cells, the latter typically best seen at the edge of palisaded histiocytic reaction around necrosis.[61,62,68] If granulomas without necrosis are present anywhere in the sample, this argues strongly against a diagnosis of WG and in favor of infection. Necrotizing vasculitis may be present but is not a requisite for the diagnosis. A diagnostic TBB in WG is presented in Figure 12, A through C.

Intravenous Drug Abuse Microangiopathy

Drug abusers who crush analgesic tablets and inject them intravenously can develop pulmonary deposition of pill-binding agents (in previous years this was talc,[69,70] but today this is typically microcrystalline cellulose[71]). This refractile material accumulates as particles (often greater than 10 μm in size) accompanied by, or within, giant cells in the perivascular sheath of small precapillary arteries.[72] Recognizing this histopathology is essential, especially in avoiding confusion with sarcoidosis. Polarization will reveal the particles, but keep in mind that polarizable particles (calcium oxylate and calcium carbonate) can be seen as a nonspecific finding in giant cells of granulomatous inflammation. Sometimes, morphologically distinctive pill components such as the disintegrant polymer crospovidone (blue) may be present, producing a deeply basophilic corallike particle.[73] Recognizing the location of refractile material deposits as being within the perivascular sheath is essential. A diagnostic TBB in ''pill-crusher'' intravenous drug abuse is presented in Figure 13, A and B.

Downloaded from https://aplm.kglmeridian.com at 2026-03-06 via free access

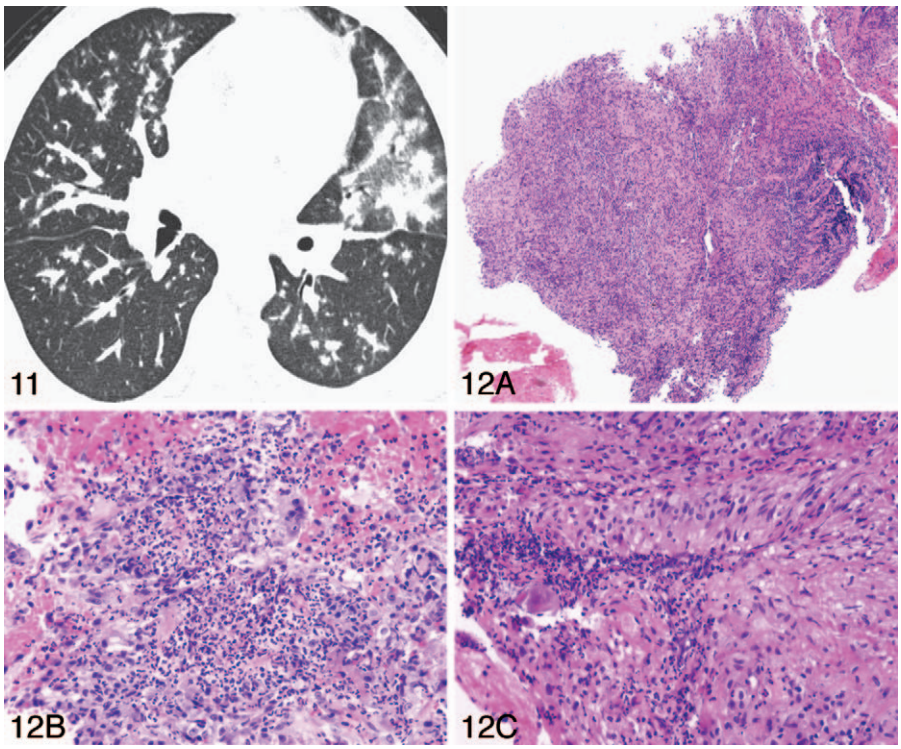

Figure 11. *Wegener granulomatosis. Axial computed tomographic image shows extensive irregular thickening of the visible bronchoarterial bundles with areas of ground-glass opacity surrounding the lesions. This is particularly evident in the lingula. The images reflect the irregular infiltration of the axial interstitium similar to the abnormalities in sarcoidosis (which is usually more nodular) and Kaposi sarcoma (which occurs in immunocompromised hosts). The ground-glass attenuation represents hemorrhage around the lesions, common in Wegener granulomatosis.*

Figure 12. *A, In classic nodular Wegener granulomatosis (WG), the transbronchial biopsy shows a dense, mixed, chronic inflammatory infiltrate (rich in plasma cells and eosinophils) that obscures underlying parenchyma (hematoxylin-eosin, original magnification ×40). B, The diagnosis begins to emerge with the presence of isolated multinucleated giant cells, often having an "osteoclast-like" appearance. At this point, a descriptive diagnosis would be appropriate, including infection (eg, abscess wall), lymphoma (especially Hodgkin disease), and WG in the differential diagnosis (hematoxylin-eosin, original magnification ×200). C, Palisaded histiocytes are present at the edge of "blue" necrosis in this case, placing WG high in the differential diagnosis. Confirmation with clinical presentation, computed tomographic findings, and serologic studies is always essential (hematoxylin-eosin, original magnification ×100).*

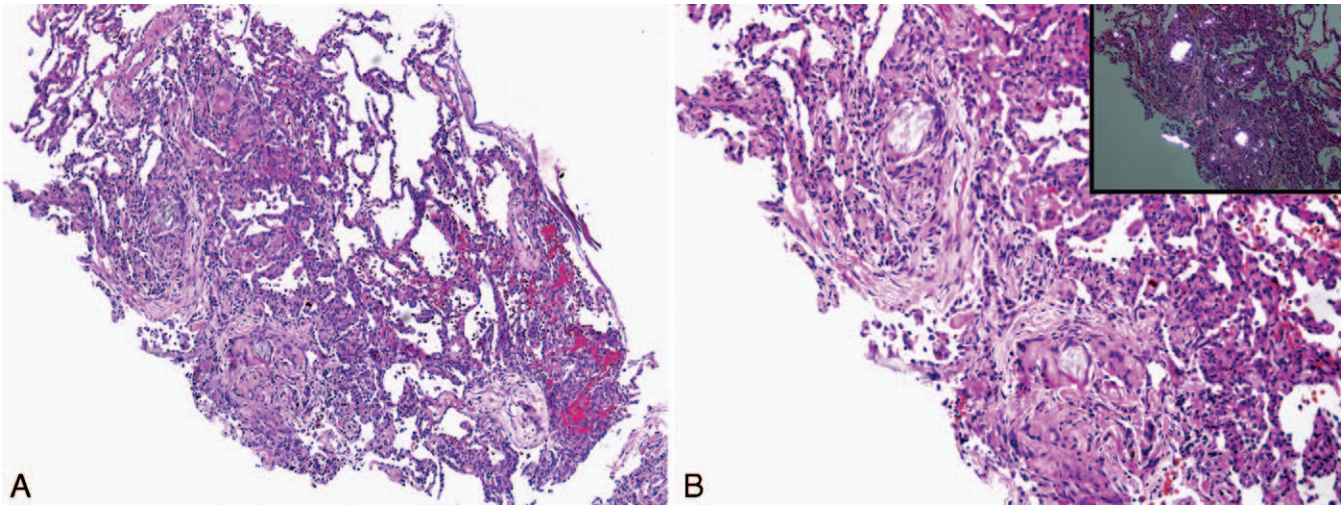

Figure 13. *Intravenous drug abuse microangiopathy. A, Two micronodules of inflammatory cells are present, surrounding aggregates of pale refractile material. No definite granulomas have formed. Elastic tissue stains can help accentuate the perivascular distribution of this material in the biopsy if there is a question (hematoxylin-eosin, original magnification ×40). B, The pill-binding material has a pale translucent appearance in this example, but basophilic material can also occur, depending on the composition of the tablets used. The relatively large size of these particles argues against an inhalational origin (the latter are typically less than 7 μm in size) (hematoxylin-eosin, original magnification ×200). Inset, The material is brightly birefringent in plane-polarized light (same original magnification).*

Alveolar Proteinosis

Clinical Scenario.—Pulmonary alveolar proteinosis (PAP) is not one disease but rather a manifestation of a number of disparate diseases and conditions.[74,75] Environmental exposure to dust of varying composition, hematolymphoid neoplasms and their associated disorders, systemic immunologic disorders, dermatomyositis, and lung transplantation have all been implicated in the etiology of PAP, and, naturally, an idiopathic form is well described.

Surfactant, produced by pulmonary type 2 alveolar lining cells, is highly regulated in terms of production and clearance. Macrophages are known to participate in the clearance of surfactant and new data have shown a central role for granulocyte monocyte colony-stimulating factor in

Downloaded from https://aplm.kglmeridian.com at 2026-03-06 via free access

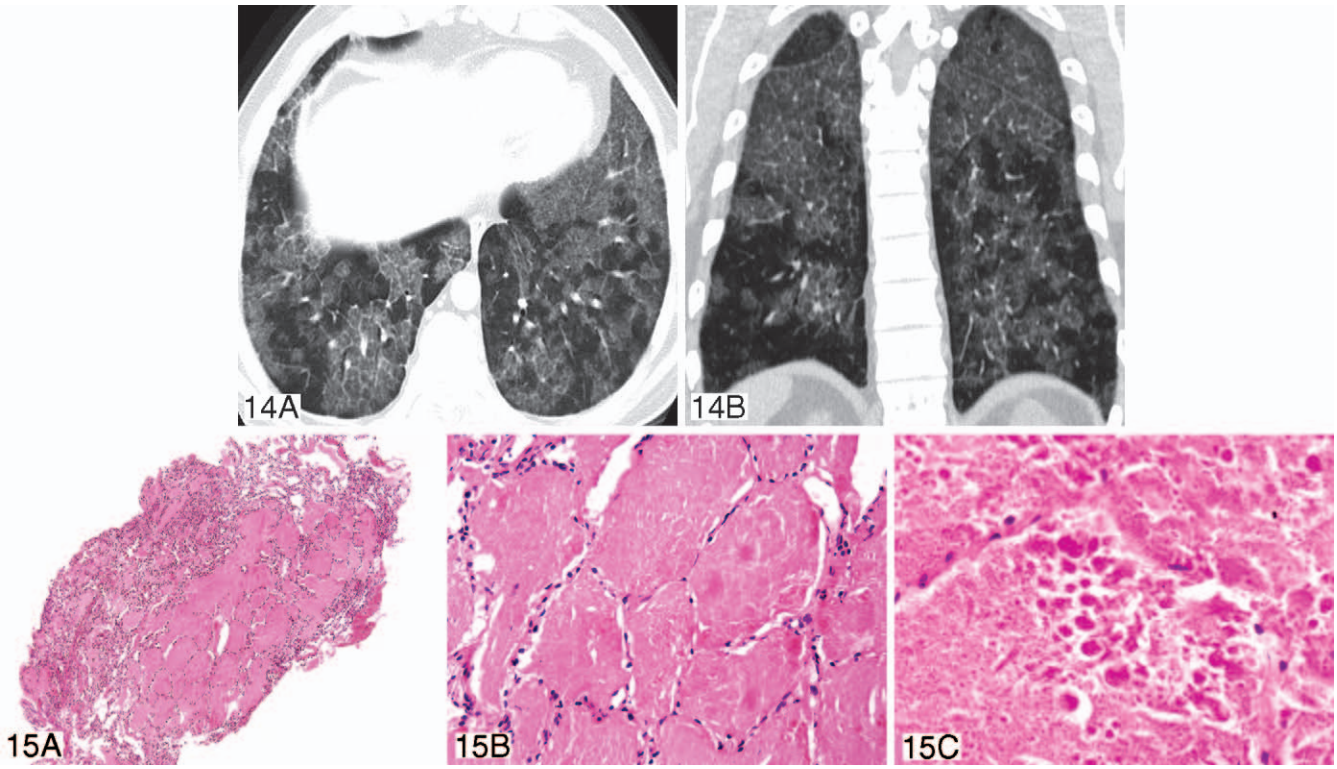

Figure 14. *Pulmonary alveolar proteinosis (PAP). A, Axial computed tomographic (CT) image through the lower lungs shows a quiltlike pattern of normal lung (dark) and extensive foci of ground-glass attenuation sharply demarcated from one another. The areas of ground-glass attenuation are superimposed on a background of interlobular septal thickening and fine intralobular lines, indicating some degree of fine fibrosis. This pattern occurs in idiopathic PAP but also in* Pneumocystis *pneumonia–associated PAP (a form of secondary alveolar proteinosis) and occasionally in pulmonary hemorrhage. B, Coronal CT image shows the alternating areas of ground-glass attenuation (superimposed on a fine reticular pattern) with areas of dark, normal lung seen to better advantage.*

Figure 15. *A, Few pulmonary diseases are as instantly recognizable as pulmonary alveolar proteinosis (PAP). At scanning magnification, alveoli are filled with granular eosinophilic material, which tends to retract slightly from adjacent alveolar walls. Note the patchy nature of the process, with some alveoli spared even in this small parenchymal sample (hematoxylin-eosin, original magnification ×40). B, At higher magnification, a mild interstitial infiltrate of lymphocytes and sometimes plasma cells may be present (ie, alveolar walls are not entirely normal). The granular appearance of PAP is essential to the diagnosis, helping differentiate PAP from dense edema (hematoxylin-eosin, original magnification ×200). C, The periodic acid–Schiff stain can be confirmatory, highlighting the larger aggregated material within the alveolar infiltrates (original magnification ×200).*

successful surfactant degradation and clearance. In PAP, abnormal surfactant metabolism presumably leads to the accumulation of this material within the alveolar spaces. In primary (idiopathic) PAP, autoantibodies directed at granulocyte monocyte colony-stimulating factor support the concept that this is an autoimmune disorder.[76]

Regardless of underlying etiology, patient complaints and physical findings are similar. Exertional dyspnea of gradual onset and accompanied by cough is typical.[77] Physical examination is frequently normal, but crackles and coarse breath sounds may be present, and clubbing has been reported in up to 25% of patients.[78] Pulmonary physiology often reflects restriction with exertional hypoxemia. Patients with PAP are at risk for secondary infections (mycobacteria and nocardia most commonly).

Radiologic Findings.—The CT findings are often diagnostic, with a pattern of normal lung alternating with sharply demarcated areas of ground-glass attenuation superimposed on a fine reticular pattern, the so-called crazy paving (Figure 14, A and B). Crazy paving is not specific for alveolar proteinosis.[79] The differential diagnosis includes *Pneumocystis* pneumonia, a cause of secondary alveolar proteinosis. In some instances, multifocal aspiration pneumonitis or organizing pneumonia/bronchiolitis obliterans organizing pneumonia can also mimic this pattern. Initially, the degree of intralobular line formation (the fine reticular pattern) is minimal, but this becomes more prominent, and the degree of architectural distortion and traction bronchiolectasis increases with the duration of the disease.

Bronchoscopic Approach.—The classic bronchoscopic description of PAP is the occurrence of a milky white bronchoalveolar lavage, a finding nearly unique to PAP. Although initially milky and opaque, after time, the fluid layers out, and a thick, proteinaceous material settles toward the bottom of the bottle. Periodic acid-Schiff histochemical staining of lavage fluid samples, following diastase digestion, can be helpful if abundant positive granular material is identified.[80]

Histopathology.—Few pulmonary diseases are as easily recognizable under the microscope as PAP. Many conditions can result in eosinophilic material accumulating in the alveolar spaces, but the granular appearance of PAP, with its scattered larger and darker ''inclusions'' and retraction at the interface with alveolar walls, is distinctive.[81] Table 7 lists conditions in which eosinophilic exudates or inclusions accumulate within alveoli. As mentioned previously, PAP occurs as primary (idiopathic) and secondary

Downloaded from https://aplm.kglmeridian.com at 2026-03-06 via free access

Table 7. Conditions Associated With Noncellular Eosinophilic Alveolar Exudates and Eosinophilic Intra-alveolar Inclusions
Edema: cardiogenic and noncardiogenic
Fibrin: acute lung injury
Hyaline membranes: diffuse alveolar damage
Necrosis: infection, infarction, tumor
Protein: alveolar proteinosis
Bone: dendriform calcification
Round calcifications: alveolar microlithiasis
Other: corpora amylacea

forms.[74,76,77,81,82] Because the secondary forms can occur in the vicinity of infection (often *Nocardia* sp) or as part of an immunologic phenomena in certain hematologic malignancies, these potential comorbidities should be considered during the histopathologic evaluation.

Under the microscope, PAP is immediately recognizable at scanning magnification by the presence of alveoli filled with eosinophilic material. The granular eosinophilic exudates within alveolar spaces are rich in surfactant and accompanied by randomly dispersed larger eosinophilic dense bodies. This material tends to pull away from nearby alveolar walls, producing a cleft or space. If in doubt, a periodic acid–Schiff stain with diastase digestion can be used for confirmation. Whenever abundant chronic inflammation is also seen, this may be a clue to the presence of the secondary form (infection or immune disorder). A diagnostic TBB from a patient with primary PAP is presented in Figure 15, A through C.

Pulmonary LCH

Clinical Scenario.—Pulmonary Langerhans cell histiocytosis (PLCH) is a smoking-related interstitial lung disease of unknown incidence and prevalence in the smoking population.[83,84] Pulmonary Langerhans cell histiocytosis occurs most commonly between the ages of 30 and 50 years, but can be seen in the older population. It has been unclear whether there is a gender bias in this disease process, although some recent studies suggest that PLCH is more common in women. Also, anecdotal cases suggest that heavy smoking is a predisposing factor, although no objective data are available to suggest a dose relationship.

The most common presenting complaint of patients with PLCH is breathlessness and nonproductive cough. Less commonly, the disease may be asymptomatic and discovered on chest imaging for other concerns. Pneumothorax occurs in a small percentage of patients (10%–15%) and as many as one third of patients will complain of generalized constitutional symptoms such as weight loss, fever, and night sweats. Superficial adenopathy, skin rash, hypothalamic manifestations, and bone pain occur in less than 15% of patients as manifestations of extrapulmonary involvement.

General physical manifestations are limited, with typically normal chest auscultation. Laboratory tests are typically unhelpful. Pulmonary function studies show reduced lung capacity most consistently, but may also show obstructive, restrictive, or mixed patterns depending on when in the course of disease patients are tested.

Radiologic Findings.—As is the case with many other diffuse or multifocal pulmonary disorders, the CT findings depend entirely on the stage of disease.[85] In the early stage, nodules measuring several millimeters in diameter dominate, usually in a centrilobular distribution with a middle and upper zonal predominance. The differential diagnosis at this stage includes granulomatous infection, sarcoidosis, and WG. Later, the nodules contain central lucencies caused by either tiny cavities or actual bronchiolar dilatation. Late disease is more cystic in nature, with variable size and shape of the cystic lesions. Costophrenic angle-sparing is a hallmark of this stage of the disease process. Although LAM is in the differential diagnosis of cystic disease, the CT findings in LAM usually are distinctive (see later discussion). Very advanced cases of LCH are indistinguishable from emphysema. Although CT can be diagnostic in mixed nodular and cystic disease with costophrenic angle-sparing in a young smoker (Figure 16, A and B), frequently the changes are suggestive, but not specific, and TBB is required.

Bronchoscopy.—Transbronchial biopsies and bronchial alveolar lavage may be diagnostic in PLCH,[86] although the sporadic occurrence of lesions makes the yield relatively low (less than 50%).[83] Exclusion of other diseases in the differential diagnosis appears to be the primary role (eg, infection, sarcoidosis, hypersensitivity pneumonitis, lymphangitic tumor). The use of immunohistochemistry on lavage material to secure a diagnosis is discouraged (CD1a and S100 protein), as Langerhans cells can be increased in the lungs of smokers (and a variety of inflammatory conditions), making a false-positive diagnosis a significant risk. Routine use of these stains on the TBB is also fraught with perils, simply because there are too many circumstances other than PLCH that may have a few Langerhans cells as a reactive phenomenon. That said, the presence of confluent S100 protein and CD1a immunostained Langerhans cells in a TBB would certainly be highly suggestive of or compatible with a diagnosis of PLCH in the proper clinical (ie, smoker) and radiologic context (see later discussion).

Histopathology.—Many of the patients who undergo flexible bronchoscopy are smokers. Smokers are at increased risk for a number of pulmonary diseases, including 3 forms of interstitial pneumonia: respiratory bronchiolitis-associated interstitial lung disease, desquamative interstitial pneumonia, and PLCH.[87,88] The incidence and prevalence of these 3 conditions in smokers is unknown. The former 2 conditions are probably not diagnosable with the TBB, although they can reasonably be suggested as a possibility when airspace macrophages of ''smokers'' type dominate the histopathology, the patient has ground-glass infiltrates, and no other findings are present to suggest an alternative diagnosis. Pulmonary LCH on the other hand is diagnosable on occasion if a characteristic lesion happens to be included in the sample. Langerhans cell histiocytosis is an airway-centered disease, so the occurrence of PLCH lesions is not unexpected in the TBB.[83,84,86,89] The difficult challenge is recognizing PLCH when lesions are only partially sampled. Knowledge of the CT findings is often helpful. We do not advise the performance of immunohistochemical stains for Langerhans cells (S100 protein and CD1a) unless the findings are compelling for PLCH, and in this setting, stains are not really required for the diagnosis. Langerhans cells may be present in a number of inflammatory conditions and increased in the lung parenchyma, potentially producing a false-positive result. A diagnostic TBB in LCH is presented in Figure 17, A and B.

Downloaded from https://aplm.kglmeridian.com at 2026-03-06 via free access

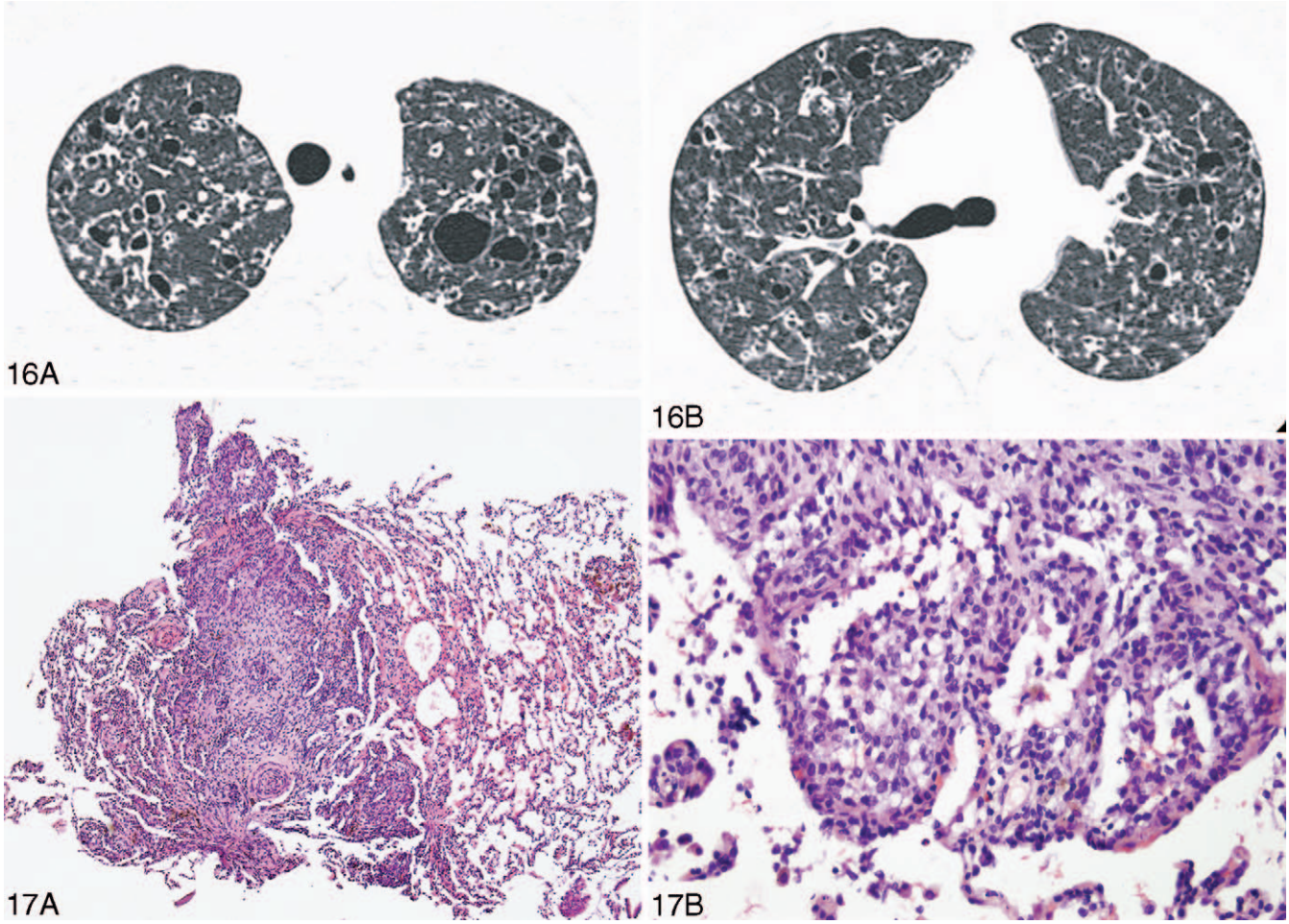

Figure 16. *Langerhans cell histiocytosis. A, Axial computed tomographic (CT) image shows multiple cystic lesions, some with irregular and bizarre shapes, in the upper lobes. Some of these may represent dilated airways, while the relationship of other lesions to the bronchioles is not clear. B, Axial CT image inferior to (A) shows fewer and smaller lesions, with vague nodularity in the right lung. The costophrenic angles in this patient were normal in appearance (not shown), characteristic of the disease.*

Figure 17. *A, When Langerhans cell histiocytosis is diagnosable in the transbronchial biopsy, the lesions tend to resemble neoplasm, as they occur as small, variably cellular, nodules. Sometimes Langerhans cell histiocytosis lesions may be mistaken for dense foci of organizing pneumonia (hematoxylin-eosin, original magnification ×40). B, At high magnification, the cellular component of the lesions is composed of characteristic Langerhans cells, with their amphophilic cytoplasm, and distinctive pale blue nuclei with sharp nuclear folds. In a lesion as characteristic as this, special stains are not necessary for a definitive diagnosis (hematoxylin-eosin, original magnification ×200).*

Lymphangioleiomyomatosis

Clinical Scenario.—Lymphangioleiomyomatosis is a rare disease of unknown etiology, characterized by the accumulation of morphologically and immunophenotypically distinctive smooth muscle along lymphatic channels in the lung and pleura, and in lymph nodes of the mediastinum, abdomen, and lower cervical chain.[90–96] Affected individuals are almost exclusively women in their childbearing years, although LAM has been reported rarely in men and can occur in postmenopausal women. The clinical presentation includes progressive breathlessness often accompanied by recurrent pneumothoraces and chylothorax. Because obstruction is almost invariably seen by pulmonary function testing, patients may be incorrectly diagnosed as having asthma. A genetic association with the tuberous sclerosis complex has been identified, but LAM can occur in the absence of this complex, and conversely, only a small fraction of individuals with tuberous sclerosis complex develop LAM.[97,98] The clinical course is variable and the current approach to therapy is hormonal.

Radiologic Findings.—Multiple thin-walled cysts in a uniform but perilymphatic distribution are most commonly present, with or without an associated pneumothorax (Figure 18).[99] The perilymphatic distribution, lack of costophrenic angle-sparing, thin walls of the cysts, and monotonous size and shape of the cysts all distinguish LAM from LCH. Smoking history favors the latter condition, and pneumothorax favors the former. The differential diagnosis is primarily that of idiopathic lymphoid interstitial pneumonia, which can also cause multiple cysts, and in a young woman, could indicate underlying connective tissue disease (eg, Sjögren syndrome) rather than LAM.

Bronchoscopic Approach.—Transbronchial biopsy can be diagnostic in LAM.[100–102] As in the case of sarcoidosis, several biopsies are more likely to be successful, given the sporadic and seemingly random distribution of diagnosable lesions. When clinical and radiologic findings are compelling for LAM, immunohistochemical staining (see following discussion) may be worthwhile, even if definite lesions are not seen. There is an increased risk for pneu-

Downloaded from https://aplm.kglmeridian.com at 2026-03-06 via free access

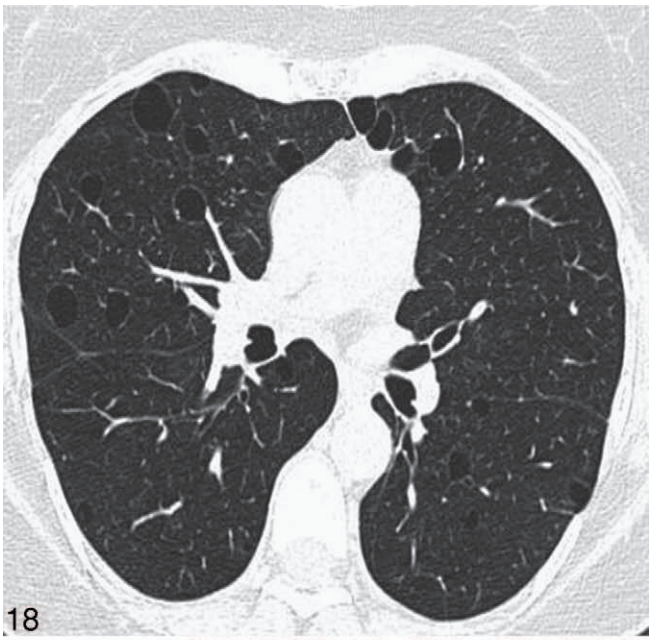

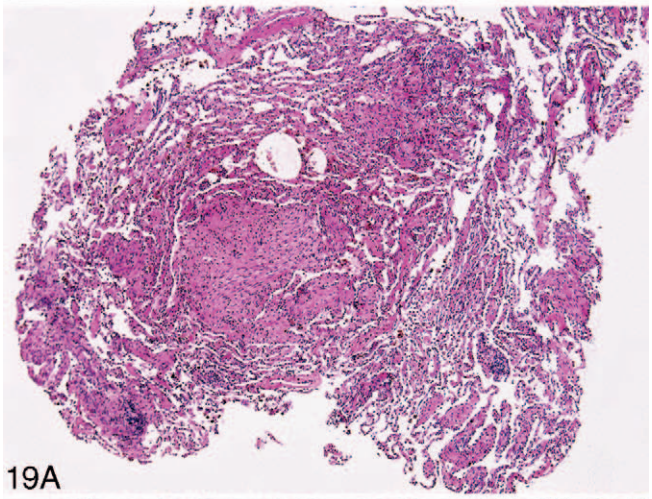

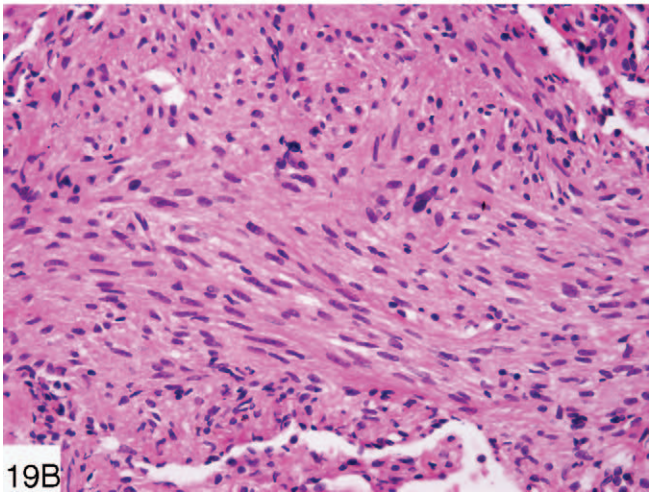

Figure 18. *Lymphangioleiomyomatosis. Axial computed tomographic image shows numerous cysts with very thin walls, in a uniform distribution throughout the lungs in a young woman. The costophrenic angles (not shown) also contained cystic lesions.*

Figure 19. *A, Lymphangioleiomyomatosis (LAM) has many histopathologic appearances, from cysts with isolated patches of abnormal smooth muscle in their walls, to larger aggregates of this distinctive smooth muscle, as seen in this example. The perilymphatic distribution of LAM makes transbronchial biopsy diagnosis possible if enough samples are obtained. The bronchoscopist may be reticent to take many biopsies for risk of pneumothorax (hematoxylin-eosin, original magnification ×40). B, At high magnification, the characteristic disorganized appearance of LAM muscle is evident. The cytoplasm of these cells tends to have a foamy appearance and the nuclei are atypical cytologically (hematoxylin-eosin, original magnification ×200).*

mothorax in LAM. This concern often tempers the desire on the part of the bronchoscopist for obtaining biopsies.

Histopathology.—Morphologically, the lesions of LAM are distinctive and, under most circumstances, are not easily confused with normal anatomic structures (like alveolar duct smooth muscle hyperplasia). The difficulty in diagnosis arises from the broad spectrum of manifestations associated with LAM. Lesions of LAM can be exuberant, raising a differential diagnosis to include metastatic low-grade sarcoma, especially in the small biopsy sample. Lymphangioleiomyomatosis lesions can be subtle and easily missed, even in the surgical lung biopsy. These lesions can be associated with prominent hemosiderosis resulting from recurrent microhemorrhages. Also, LAM lesions are characteristically associated with cyst formation, and sometimes the cysts dominate the histopathologic picture.

In the TBB, clues to the diagnosis of LAM begin with the clinical history and CT findings. The radiologic findings can be diagnostic, but the rarity of the disease and the implications of the diagnosis make a tissue sampling almost a prerequisite. Without a clinical or radiologic suspicion of LAM, the pathologist must rely on recognizing the characteristic, slightly disorganized appearance of LAM smooth muscle and characteristic vacuolation of the cytoplasm.[96,103,104] Lymphangioleiomyomatosis lesions are eosinophilic on hematoxylin-eosin–stained sections and may be missed on cursory perusal of the TBB at scanning magnification. If one or more lesions are suspected, estrogen receptor and HMB-45 immunohistochemical stains can be performed to confirm the diagnosis. Smooth muscle of LAM also expresses actin, desmin, progesterone receptors, and MART1. Another lesion that can occur in association with LAM is so-called micronodular pneumocyte hyperplasia. This epithelial lesion resembles atypical adenomatous hyperplasia to some extent, and would be difficult to distinguish accurately in small biopsy samples. A diagnostic TBB in LAM is presented in Figure 19, A and B.

SUMMARY AND CONCLUSIONS

The transbronchial biopsy is a powerful tool for diagnosis when applied with realistic expectations on the part of both clinicians and pathologists and knowledge of the diseases and conditions that are likely to be successfully biopsied. Computed tomography context is often essential both for choosing appropriate patients to undergo biopsy and in the accurate interpretation of biopsy findings. An overview has been presented of the nonneoplastic conditions most commonly diagnosed using this procedure. Close interaction between pulmonologist, radiologist, and pathologist enhances the utility of the TBB and improves the quality of patient care.

Downloaded from https://aplm.kglmeridian.com at 2026-03-06 via free access

References

1. Leoncini B, Palatresi R. Transbronchial lung biopsy (a technical contribution). *Dis Chest.* 1968;53:736–742.
2. Smart J. Transbronchial pulmonary biopsy. *Thorax.* 1966;21:444.
3. Churg A, Schwarz M. Transbronchial biopsy and usual interstitial pneumonia: a new paradigm? *Chest.* 2006;129:1117–1118.
4. Berbescu EA, Katzenstein AL, Snow JL, Zisman DA. Transbronchial biopsy in usual interstitial pneumonia. *Chest.* 2006;129:1126–1131.
5. Kendall DM, Gal AA. Interpretation of tissue artifacts in transbronchial lung biopsy specimens. *Ann Diagn Pathol.* 2003;7:20–24.
6. Milman N, Faurschou P, Munch EP, Grode G. Transbronchial lung biopsy through the fibre optic bronchoscope: results and complications in 452 examinations. *Respir Med.* 1994;88:749–753.
7. Tazelaar H, Nillson F, Rinaldi M, et al. The sensitivity of transbronchial biopsy for the diagnosis of acute lung rejection. *J Thorac Cardiovasc Surg.* 1993; 105:674–678.
8. Sibley R, Berry G, Tazelaar H, et al. The role of transbronchial biopsies in the management of lung transplant recipients. *J Heart Lung Transplant.* 1993;12: 308–324.
9. Takayama K, Nagata N, Miyagawa Y, Hirano H, Shigematsu N. The usefulness of step sectioning of transbronchial lung biopsy specimen in diagnosing sarcoidosis. *Chest.* 1992;102:1441–1443.
10. Fraire AE, Cooper SP, Greenberg SD, Rowland LP, Langston C. Transbronchial lung biopsy: histopathologic and morphometric assessment of diagnostic utility. *Chest.* 1992;102:748–752.
11. Poletti V, Patelli M, Poggi S, Bertanti T, Spiga L, Ferracini R. Transbronchial lung biopsy and bronchoalveolar lavage in diagnosis of diffuse infiltrative lung diseases. *Respiration.* 1988;54(suppl 1):66–72.
12. Poletti V, Patelli M, Ferracini R, Simonetti M, Spiga L. Transbronchial lung biopsy in infiltrative lung disease: the importance of the pathologic approach. *Sarcoidosis.* 1988;5:43–50.
13. Blumenfeld W, Wagar E, Hadley WK. Use of the transbronchial biopsy for diagnosis of opportunistic pulmonary infections in acquired immunodeficiency syndrome (AIDS). *Am J Clin Pathol.* 1984;81:1–5.
14. Puksa S, Hutcheon MA, Hyland RH. Usefulness of transbronchial biopsy in immunosuppressed patients with pulmonary infiltrates. *Thorax.* 1983;38:146–150.
15. Wall C, Gaensler E, Carrington C, Hayes J. Comparison of transbronchial and open biopsies in chronic infiltrative lung disease. *Am Rev Respir Dis.* 1981; 123:280–285.
16. Mitchell DM, Emerson CJ, Collins JV, Stableforth DE. Transbronchial lung biopsy with the fibreoptic bronchoscope: analysis of results in 433 patients. *Br J Dis Chest.* 1981;75:258–262.
17. Zavala DC. Transbronchial biopsy in diffuse lung disease. *Chest.* 1978;73: 727–733.
18. Smith CW, Murray GF, Wilcox BR, Starek PJ, Delany DJ. The role of transbronchial lung biopsy in diffuse pulmonary disease. *Ann Thorac Surg.* 1977;24: 54–58.
19. Andersen HA. Transbronchial lung biopsy in diffuse pulmonary disease. *Ann Thorac Surg.* 1977;24:1.
20. Churg A. Transbronchial biopsy: nothing to fear. *Am J Surg Pathol.* 2001; 25:820–822.
21. Aziz ZA, Wells AU, Hansell DM, et al. HRCT diagnosis of diffuse parenchymal lung disease: inter-observer variation. *Thorax.* 2004;59:506–511.
22. Gruden JF, Webb WR, Naidich DP, McGuinness G. Multinodular disease: anatomic localization at thin-section CT–multireader evaluation of a simple algorithm. *Radiology.* 1999;210:711–720.
23. Utz JP, Ryu JH, Douglas WW, et al. High short-term mortality following lung biopsy for usual interstitial pneumonia. *Eur Respir J.* 2001;17:175–179.
24. Hernandez Blasco L, Sanchez Hernandez IM, Villena Garrido V, de Miguel Poch E, Nunez Delgado M, Alfaro Abreu J. Safety of the transbronchial biopsy in outpatients. *Chest.* 1991;99:562–565.
25. Luce JM. Acute lung injury and the acute respiratory distress syndrome. *Crit Care Med.* 1998;26:369–376.
26. Downey GP, Granton JT. Mechanisms of acute lung injury. *Curr Opin Pulm Med.* 1997;3:234–241.
27. Camus PH, Foucher P, Bonniaud PH, Ask K. Drug-induced infiltrative lung disease. *Eur Respir J Suppl.* 2001;32:93s–100s.
28. Lamblin C, Bergoin C, Saelens T, Wallaert B. Interstitial lung diseases in collagen vascular diseases. *Eur Respir J Suppl.* 2001;32:69s–80s.
29. Hunninghake G, Fauci A. Pulmonary involvement in the collagen vascular diseases. *Am Rev Respir Dis.* 1979;119:471–503.
30. Nicholson AG, Colby TV, Wells AU. Histopathological approach to patterns of interstitial pneumonia in patient with connective tissue disorders. *Sarcoidosis Vasc Diffuse Lung Dis.* 2002;19:10–17.
31. Schwarz MI, Matthay RA, Sahn SA, Stanford RE, Marmorstein BL, Scheinhorn DJ. Interstitial lung disease in polymyositis and dermatomyositis: analysis of six cases and review of the literature. *Medicine (Baltimore).* 1976;55:89–104.
32. Fata F, Rathore R, Schiff C, Herzlich BC. Bronchiolitis obliterans organizing pneumonia as the first manifestation of polymyositis. *South Med J.* 1997;90:227–230.
33. Cordier J, Loire R, Brune J. Idiopathic bronchiolitis obliterans organizing pneumonia: definition of clinical profiles in a series of 16 patients. *Chest.* 1989; 96:999–1004.
34. Colby TV. Pathologic aspects of bronchiolitis obliterans organizing pneumonia. *Chest.* 1992;102:38S–43S.
35. Epler GR, Colby TV, McLoud TC, Carrington CB, Gaensler EA. Bronchiolitis obliterans organizing pneumonia. *N Engl J Med.* 1985;312:152–158.
36. Beasley MB, Franks TJ, Galvin JR, Gochuico B, Travis WD. Acute fibrinous and organizing pneumonia: a histological pattern of lung injury and possible variant of diffuse alveolar damage. *Arch Pathol Lab Med.* 2002;126:1064–1070.
37. Crofton JW, Livingstone JL, Oswald NC, Roberts AT. Pulmonary eosinophilia. *Thorax.* 1952;7:1–35.
38. Liebow A, Carrington C. The eosinophilic pneumonias. *Medicine (Baltimore).* 1969;48:251–285.
39. Allen JN, Davis WB. Eosinophilic lung diseases. *Am J Respir Crit Care Med.* 1994;150:1423–1438.
40. Tazelaar HD, Linz LJ, Colby TV, Myers JL, Limper AH. Acute eosinophilic pneumonia: histopathologic findings in nine patients. *Am J Respir Crit Care Med.* 1997;155:296–302.
41. Johkoh T, Muller NL, Akira M, et al. Eosinophilic lung diseases: diagnostic accuracy of thin-section CT in 111 patients. *Radiology.* 2000;216:773–780.
42. Colby TV, Fukuoka J, Ewaskow SP, Helmers R, Leslie KO. Pathologic approach to pulmonary hemorrhage. *Ann Diagn Pathol.* 2001;5:309–319.
43. Hogan PG, Donald KJ, McEvoy JD. Immunofluorescence studies of lung biopsy tissue. *Am Rev Respir Dis.* 1978;118:537–545.
44. Katzenstein AL, Fiorelli RF. Nonspecific interstitial pneumonia/fibrosis: histologic features and clinical significance. *Am J Surg Pathol.* 1994;18:136–147.
45. Raoof S, Raoof S, Naidich DP. Imaging of unusual diffuse lung diseases. *Curr Opin Pulm Med.* 2004;10:383–389.
46. Hammar S. Hypersensitivity pneumonitis: part 1. *Pathol Ann.* 1988;23: 195–216.
47. Kawanami O, Basset F, Barrios R, et al. Hypersensitivity pneumonitis in man: light and electron microscopic studies of 18 lung biopsies. *Am J Pathol.* 1983;110:275–289.
48. Colby T, Coleman A. Histologic differential diagnosis of extrinsic allergic alveolitis. *Prog Surg Pathol.* 1989;10:11–26.
49. Coleman A, Colby TV. Histologic diagnosis of extrinsic allergic alveolitis. *Am J Surg Pathol.* 1988;12:514–518.
50. Martin WJ II, Iannuzzi MC, Gail DB, Peavy HH. Future directions in sarcoidosis research: summary of an NHLBI working group. *Am J Respir Crit Care Med.* 2004;170:567–571.
51. Borchers AT, So C, Naguwa SM, Keen CL, Gershwin ME. Clinical and immunologic components of sarcoidosis. *Clin Rev Allergy Immunol.* 2003;25: 289–303.
52. Baughman RP, Lower EE, du Bois RM. Sarcoidosis. *Lancet.* 2003;361: 1111–1118.
53. Statement on sarcoidosis: the Joint Statement of the American Thoracic Society (ATS), the European Respiratory Society (ERS) and the World Association of Sarcoidosis and Other Granulomatous Disorders (WASOG) was adopted by the ATS Board of Directors and by the ERS Executive Committee, February 1999. *Am J Respir Crit Care Med.* 1999;160:736–755.
54. Brauner M, Grenier P, Mompoint D, et al. Pulmonary sarcoidosis: evaluation with high resolution CT. *Radiology.* 1989;172:467–471.
55. Müller N, Kullnig P, Miller R. The CT findings of sarcoidosis: analysis of 25 patients. *AJR Am J Roentgenol.* 1989;152:1179–1182.
56. Naidich DP, Harkin TJ. Airways and lung: correlation of CT with fiberoptic bronchoscopy. *Radiology.* 1995;197:1–12.
57. Gilman MJ, Wang KP. Transbronchial lung biopsy in sarcoidosis: an approach to determine the optimal number of biopsies. *Am Rev Respir Dis.* 1980; 122:721–724.
58. Hsu RM, Connors AF Jr, Tomashefski JF Jr Histologic, microbiologic, and clinical correlates of the diagnosis of sarcoidosis by transbronchial biopsy. *Arch Pathol Lab Med.* 1996;120:364–368.
59. Cheung O, Muhm J, Helmers R, et al. Surgical pathology of granulomatous interstitial pneumonia. *Ann Diagn Pathol.* 2003;7:127–138.
60. Rossman MD, Kreider ME. Is chronic beryllium disease sarcoidosis of known etiology? *Sarcoidosis Vasc Diffuse Lung Dis.* 2003;20:104–109.
61. Yi ES, Colby TV. Wegener's granulomatosis. *Semin Diagn Pathol.* 2001;18: 34–46.
62. Colby TV, Specks U. Wegener's granulomatosis in the 1990s: a pulmonary pathologist's perspective. *Monogr Pathol.* 1993:195–218.
63. Colby T. Diffuse pulmonary hemorrhage in Wegener's granulomatosis. *Semin Respir Med.* 1989;10:136–140.
64. Lohrmann C, Uhl M, Kotter E, Burger D, Ghanem N, Langer M. Pulmonary manifestations of wegener granulomatosis: CT findings in 57 patients and a review of the literature. *Eur J Radiol.* 2005;53:471–477.
65. Daum TE, Specks U, Colby TV, et al. Tracheobronchial involvement in Wegener's granulomatosis. *Am J Respir Crit Care Med.* 1995;151:522–526.
66. Lombard CM, Duncan SR, Rizk NW, Colby TV. The diagnosis of Wegener's granulomatosis from transbronchial biopsy specimens. *Hum Pathol.* 1990;21: 838–842.
67. Givens CD Jr, Newman JH, McCurley TL. Diagnosis of Wegener's granulomatosis by transbronchial biopsy. *Chest.* 1985;88:794–796.
68. Mark J, Matsubara O, Tau-Liu N, Fienberg R. The pulmonary biopsy in the early diagnosis of Wegener's (pathergic) granulomatosis. *Hum Pathol.* 1988;19: 1065–1071.
69. Genereux GP, Emson HE. Talc granulomatosis and angiothrombotic pulmonary hypertension in drug addicts. *J Can Assoc Radiol.* 1974;25:87–93.

Downloaded from https://aplm.kglmeridian.com at 2026-03-06 via free access

70. Hopkins GB, Taylor DG. Pulmonary talc granulomatosis: a complication of drug abuse. *Am Rev Respir Dis.* 1970;101:101–104.
71. Tomashefski JF Jr, Hirsch CS, Jolly PN. Microcrystalline cellulose pulmonary embolism and granulomatosis: a complication of illicit intravenous injections of pentazocine tablets. *Arch Pathol Lab Med.* 1981;105:89–93.
72. Tomashefski J, Hirsch C. The pulmonary vascular lesions of intravenous drug abuse. *Hum Pathol.* 1980;11:133–145.
73. Ganesan S, Felo J, Saldana M, Kalasinsky VF, Lewin-Smith MR, Tomashefski JF Jr. Embolized crospovidone (poly[N-vinyl-2-pyrrolidone]) in the lungs of intravenous drug users. *Mod Pathol.* 2003;16:286–292.
74. Seymour J, Presneill J. Pulmonary alveolar proteinosis: progress in the first 44 years. *Am J Respir Crit Care Med.* 2002;166:215–235.
75. Shah P, Hansell D, Lawson P, Reid K, Morgan C. Pulmonary alveolar proteinosis: clinical aspects and current concepts in pathogenesis. *Thorax.* 2000;55:67–77.
76. Costabel U, Guzman J. Pulmonary alveolar proteinosis: a new autoimmune disease. *Sarcoidosis Vasc Diffuse Lung Dis.* 2005;22(suppl 1):67–73.
77. Claypool W, Roger R, Matuschak G. Update on the clinical diagnosis, management, and pathogenesis of pulmonary alveolar proteinosis (phospholipidosis). *Chest.* 1984;85:550–558.
78. Goldstein LS, Kavuru MS, Curtis-McCarthy P, Christie HA, Farver C, Stoller JK. Pulmonary alveolar proteinosis: clinical features and outcomes. *Chest.* 1998;114:1357–1362.
79. Rossi SE, Erasmus JJ, Volpacchio M, Franquet T, Castiglioni T, McAdams HP. ''Crazy-paving'' pattern at thin-section CT of the lungs: radiologic-pathologic overview. *Radiographics.* 2003;23:1509–1519.
80. Maygarden SJ, Iacocca MV, Funkhouser WK, Novotny DB. Pulmonary alveolar proteinosis: a spectrum of cytologic, histochemical, and ultrastructural findings in bronchoalveolar lavage fluid. *Diagn Cytopathol.* 2001;24:389–395.
81. Davidson J, MacLeod W. Pulmonary alveolar proteinosis. *Br J Dis Chest.* 1969;63:13–16.
82. Miller R, Churg A, Hutcheon M, Lam S. Pulmonary alveolar proteinosis and aluminum dust exposure. *Am Rev Respir Dis.* 1984;130:312–315.
83. Vassallo R, Ryu JH, Colby TV, Hartman T, Limper AH. Pulmonary Langerhans'-cell histiocytosis. *N Engl J Med.* 2000;342:1969–1978.
84. Travis WD, Borok Z, Roum JH, et al. Pulmonary Langerhans cell granulomatosis (histiocytosis X): a clinicopathologic study of 48 cases. *Am J Surg Pathol.* 1993;17:971–986.
85. Brauner MW, Grenier P, Tijani K, Battesti JP, Valeyre D. Pulmonary Langerhans cell histiocytosis: evolution of lesions on CT scans. *Radiology.* 1997;204:497–502.
86. Housini I, Tomashefski JF Jr, Cohen A, Crass J, Kleinerman J. Transbronchial biopsy in patients with pulmonary eosinophilic granuloma: comparison with findings on open lung biopsy. *Arch Pathol Lab Med.* 1994;118:523–530.
87. Aubry MC, Wright JL, Myers JL. The pathology of smoking-related lung diseases. *Clin Chest Med.* 2000;21:11–35, vii.
88. Ryu JH, Colby TV, Hartman TE, Vassallo R. Smoking-related interstitial lung diseases: a concise review. *Eur Respir J.* 2001;17:122–132.
89. Yousem SA, Colby TV, Chen YY, Chen WG, Weiss LM. Pulmonary Langerhans' cell histiocytosis: molecular analysis of clonality. *Am J Surg Pathol.* 2001;25:630–636.
90. Ferrans VJ, Yu ZX, Nelson WK, et al. Lymphangioleiomyomatosis (LAM): a review of clinical and morphological features. *J Nippon Med Sch.* 2000;67:311–329.
91. Carrington C, Cugell D, Gaensler E, et al. Lymphangioleiomyomatosis: physiologic-pathologic-radiologic correlations. *Am Rev Respir Dis.* 1977;116:977–995.
92. Templeton P, McLoud T, Müller N, et al. Pulmonary lymphangioleiomyomatosis: CT and pathologic findings. *J Comput Assist Tomogr.* 1989;13:54–57.
93. Taylor JR, Ryu J, Colby TV, Raffin TA. Lymphangioleiomyomatosis: clinical course in 32 patients. *N Engl J Med.* 1990;323:1254–1260.
94. Costello LC, Hartman TE, Ryu JH. High frequency of pulmonary lymphangioleiomyomatosis in women with tuberous sclerosis complex. *Mayo Clin Proc.* 2000;75:591–594.
95. Carsillo T, Astrinidis A, Henske EP. Mutations in the tuberous sclerosis complex gene TSC2 are a cause of sporadic pulmonary lymphangioleiomyomatosis. *Proc Natl Acad Sci U S A.* 2000;97:6085–6090.
96. Kitaichi M, Nishimura K, Itoh H, Izumi T. Pulmonary lymphangioleiomyomatosis: a report of 46 patients including a clinicopathologic study of prognostic factors. *Am J Respir Crit Care Med.* 1995;151:527–533.
97. Hancock E, Tomkins S, Sampson J, Osborne J. Lymphangioleiomyomatosis and tuberous sclerosis. *Respir Med.* 2002;96:7–13.
98. Sato T, Seyama K, Fujii H, et al. Mutation analysis of the TSC1 and 7TC2 genes in Japanese patients with pulmonary lymphangioleiomyomatosis. *J Hum Genet.* 2002;47:20–28.
99. Kirchner J, Stein A, Viel K, et al. Pulmonary lymphangioleiomyomatosis: high-resolution CT findings. *Eur Radiol.* 1999;9:49–54.
100. Naalsund A, Johansen B, Foerster A, Kolbenstvedt A. When to suspect and how to diagnose pulmonary lymphangioleiomyomatosis. *Respirology.* 1996;1:207–212.
101. Kitaichi M, Izumi T. Lymphangioleiomyomatosis. *Curr Opin Pulm Med.* 1995;1:417–424.
102. Delgrange E, Delgrange B, Wallon J, Rosoux P. Diagnostic approach to pulmonary lymphangioleiomyomatosis. *J Intern Med.* 1994;236:461–464.
103. Urban T, Lazor R, Lacronique J, et al. Pulmonary lymphangioleiomyomatosis: a study of 69 patients. Groupe d'Etudes et de Recherche sur les Maladies ''Orphelines'' Pulmonaires (GERM''O''P). *Medicine (Baltimore).* 1999;78:321–337.
104. Chu SC, Horiba K, Usuki J, et al. Comprehensive evaluation of 35 patients with lymphangioleiomyomatosis. *Chest.* 1999;115:1041–1052.

Downloaded from https://aplm.kglmeridian.com at 2026-03-06 via free access